

Congenital midline nasal dermoid sinus cyst- our experience

Nilam Sathe^{1*}, Dhanashree Chiplunkar², Pravin Misal³, Swapnal Sawarkar⁴

¹Associate Professor, ²Assistant Professor, ^{3,4}Senior Resident, Dept. of ENT, Seth G. S. Medical College & KEM Hospital Patel, Mumbai, Maharashtra, India

Abstract

Introduction: Nasofrontal Dermoid Sinus Cyst originates from ectoderm. Ectoderm is derived from neuroectoderm & ectodermal inspiration. It may present as midline nasal pit, fistula or infected mass anywhere from glabella to columella. Sometimes it may present as single cutaneous tract with hair at the opening. It may secrete pus or sebaceous discharge. Investigation is in the form of radiological imaging mainly CT scan with or without MRI of nose and paranasal sinuses to rule out intracranial extension. Treatment is the surgical excision of entire tract to prevent recurrence.

Case Reports: We are presenting 6 cases with complaints of either nasal fistula or nasal swelling or lateral nasal wall defect. The selected age group ranging between 3 to 18 years and presenting the comprehensive discussion about diagnosis, embryology & management.

Conclusion: Among the midline nasal masses, congenital dermoid cyst & sinuses are very rare anomalies & are important because of their high propensity of intracranial extension. The CT and/or MRI is needed to rule out such extensions. Treatment is complete surgical excision. External rhinoplasty approach is preferred as it gives good exposure, good cosmetic results.

Keywords: Congenital, Nasal dermoid sinus cyst.

Introduction

Midline congenital nasal masses are very rare congenital anomalies. The incidences estimated are 1 in 20,000 to 40,000 live births.^{1,3} It includes Gliomas, Encephaloceles & Nasofrontal Dermoid Sinus Cyst (NDSC).^{2,4,7} Differential diagnosis includes inflammatory lesions, post-traumatic lesions, benign or malignant neoplasm and vascular lesions.^{1,7} It accounts for 1-3% of all dermoid in body & 11-12% of head & neck region.^{2,9,10} Most of the lesions can be detected in the first 3 years of age but in some undiagnosed or untreated cases, diagnosis can be delayed to later age.^{4,7,11} These lesions are of importance because of their tendency of intracranial extension.²

Nasofrontal Dermoid Sinus Cyst originates from ectoderm which is derived from neuroectoderm & ectodermal inseparation.³ It may present as midline nasal pit, fistula or infected mass anywhere from glabella to columella. Sometimes it may present as single cutaneous tract with hair at the opening. It may secrete pus or sebaceous discharge. Investigation is in the form of radiological imaging mainly CT with or without MRI to rule out intracranial extension. Treatment is surgical excision of the entire tract to prevent recurrence.

We present 6 cases with complaints of either nasal fistula or swelling or lateral nasal wall defect from age ranging from 3 to 18 years and the comprehensive discussion about diagnosis, embryology & management.

Materials and Methods

Case 1

11-years old boy presented with complaints of soft cystic swelling over dorsum of nose with fistula (Fig. 1) opening with sebaceous discharge & hairs seen in the opening since

birth. Rest of ENT examination was normal. Patient underwent CT PNS which showed soft tissue swelling in prenasal space with communicating sinus tract. No intracranial or intranasal extension seen on CT. Under General anesthesia, external rhinoplasty surgical approach was taken, entire length of sinus tract with cyst removed (Fig. 2). There was splaying of underlying nasal bones seen. Postoperative period was uneventful. Patient was followed up for a period of 6 months & no recurrence was seen.

Case 2

3 years old boy presented with complaints of fistula opening at tip of nose (Fig. 3) with sebaceous discharge since birth. Rest of the ENT examination was normal. CT scan of Paranasal sinus & nose was suggestive of soft tissue lesion superior to bony septum with communicating sinus tract to nasal tip with 5.8 mm bony defect in anterior cranial fossa (Fig. 4). No intranasal extension seen on CT. Under General anesthesia, external rhinoplasty surgical approach was taken; entire length of sinus tract was excised with curetting of underlying bone done. No intracranial extension found during surgery which was confirmed by checking with 0-degree sinuscope. Postoperative period was uneventful & no recurrence was seen till 6 months of follow up.

Case 3

9 years old boy presented with complaints of fistula opening with sebaceous discharge & hair seen in opening over dorsum of nose since birth. He had circular scar of 1 cm of spontaneously burst opened abscess over the left nasal bone few mm above left medial canthus. Rest of the ENT examination was normal. CT of Paranasal sinus & nose showed soft tissue lesion in prenasal space with

*Corresponding Author: Nilam Sathe, Dept. of ENT, Seth G. S. Medical College & KEM Hospital Patel, Mumbai, Maharashtra, India
Email: drneelam_S@yahoo.co.in

communicating sinus tract. No intracranial or intranasal extension was found on CT. Patient was posted for surgery under General anesthesia, elliptical incision taken around the sinus tract with entire length of tract & scarred tissue removed. Postoperative no recurrence found till 6 months follow up period.

Case 4

15 years old girl presented with 1x 0.5 cm defect in left nasal bone few mm anterior to left medial canthus with surrounding scarred tissue for 12 years (Figure 5). She presented with history of recurrent swelling over left side of nasal dorsum which spontaneous bursting & discharge till 3 years of age. Nasal cavity seen through defect was normal (Fig. 6). CT of Paranasal sinus & nose showed bony defect of 6-7 mm in left nasal bone communicating with ethmoid (Fig. 7). No intracranial extension seen on CT. Under general anesthesia, elliptical incision taken around the defect, skin tract with scarred tissue excised completely. Mucosal & skin layer was separated & mobilized. Piece of septal cartilage was harvested to seal the defect (Fig. 8). Primary skin closure was done. Good cosmetic outcome seen within 6 months of follow up postoperatively.

Case 5

18-year-old male presented with fistula opening at nasal dorsum with sebaceous discharge & hair seen in opening (Fig. 9). Rest of the ENT examination was normal. CTscan of Paranasal sinuses & nose showed well defined swelling superior to bony septum with communicating sinus tract. No intracranial or intranasal extension seen on CT. Under general anesthesia surgical excision was done. Elliptical incision was taken around the opening, entire length of sinus tract with cyst including surrounding skin was removed which had hairs with sebaceous content in it (Fig. 10). Splaying of underlying bone was seen. No recurrence found till 6 months follow up due to complete removal of the lesion.

Case 6

3 years old boy presented with 1x1 cm soft fluctuating swelling over left side of glabella (Fig. 11). Rest of the ear, nose, and throat examination was normal. CT scan of Paranasal sinuses & nose showed soft tissue swelling superior to left nasal bone. No intracranial or intranasal extension was seen on CT scan. Entire cyst was removed by surgical excision of the swelling using elliptical incision under general anesthesia. Postoperatively no recurrence was found till 6 months of follow up

Results

All 6 cases presented with variable presentation ranging from cystic swelling or fistula opening with sebaceous discharge & hairs seen in opening or defect in left nasal bone either over the nasal tip, nasal dorsum or over left nasal bone. Mean age at the time of surgery was 9.8 years and male to female ratio was 5:1. All the cases were sporadic; no familial association was seen. None of the

cases had other congenital anomalies. CT scan of paranasal sinuses & nose was done in all cases to rule out intracranial extension. Though it was seen in one of the cases but not found intraoperatively. All cases underwent surgical excision of entire length of sinus tract with cyst either by external rhinoplasty approach or by direct elliptical incision around the tract. Due to in toto removal of lesions none of the cases showed recurrence till 6 months of follow up period.

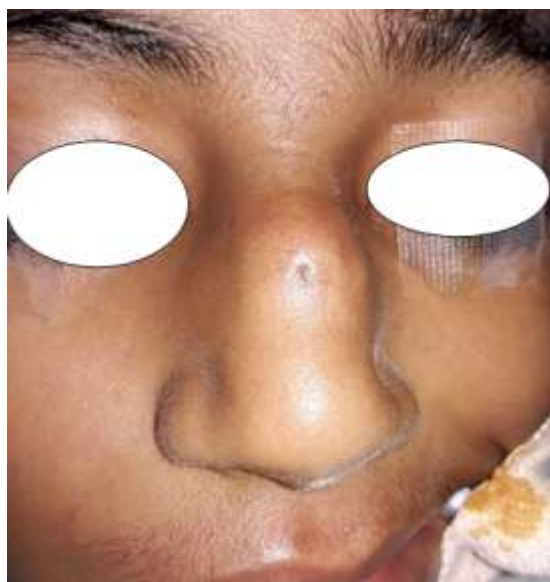

Fig. 1: Showing soft cystic swelling over dorsum of nose with fistula opening

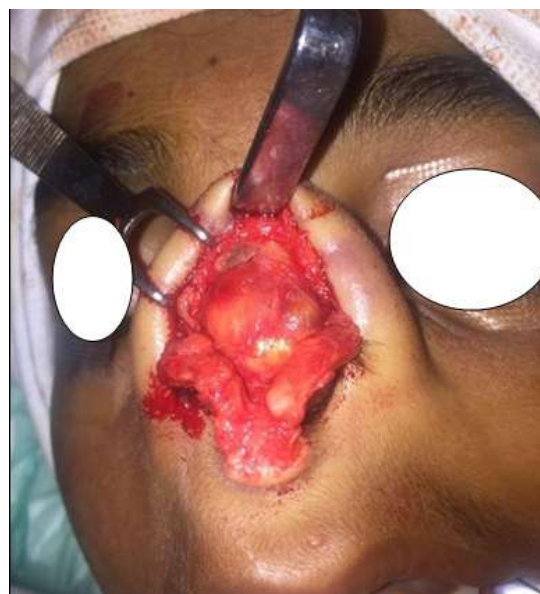

Fig. 2: Showing external rhinoplasty surgical approach was for entire length of sinus tract with cyst removal

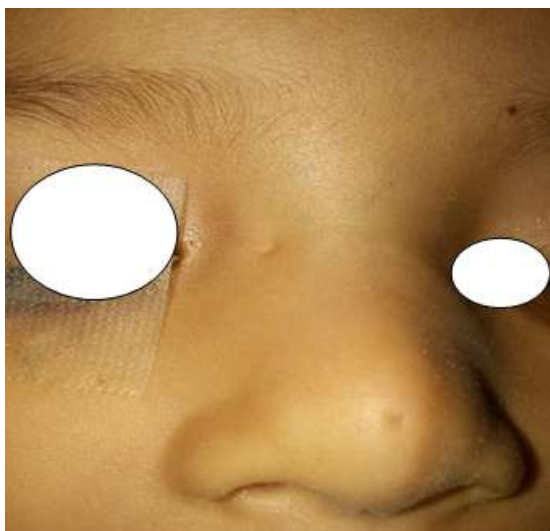


Fig. 3: Showing soft tissue lesion superior to bony septum with communicating sinus tract To nasal tip

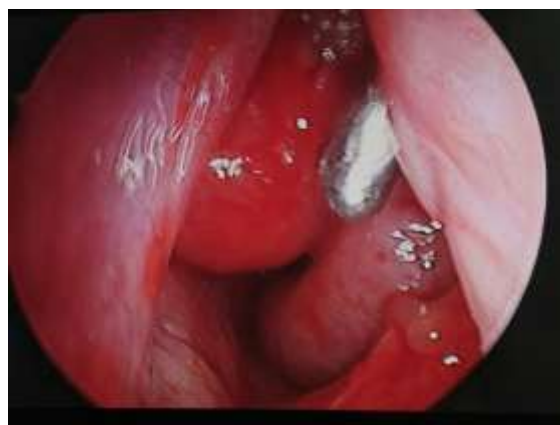

Fig. 6: Showing endoscopic picture of left nostril in which probe is seen coming in the Nasal cavity through external lateral nasal wall defect

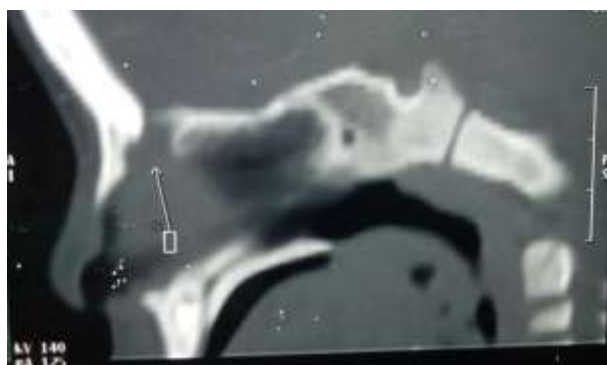

Fig. 4: CT scan showing soft tissue lesion superior to bony septum with communicating sinus tract to nasal tip with 5.8 mm bony defect in anterior cranial fossa.

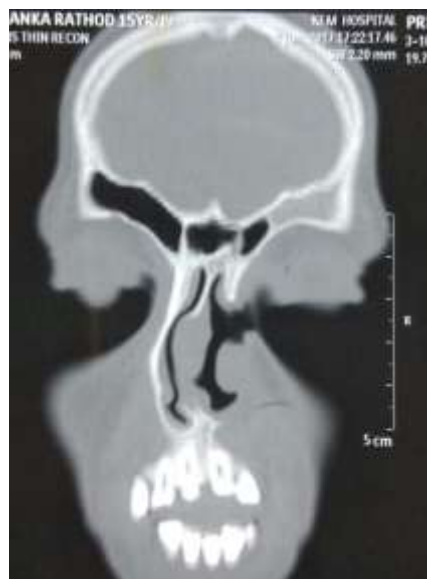


Fig. 7: CT of Paranasal sinus & nose showed bony defect of 6-7 mm in left nasal bone communicating with ethmoid.

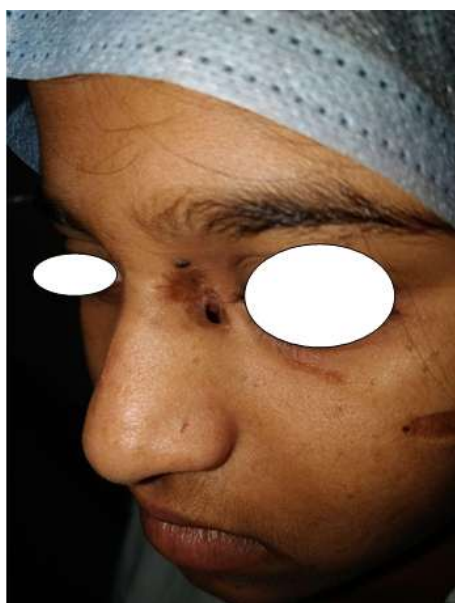

Fig. 5: defect in left nasal bone few mm anterior to left medial canthus with surrounding scarred tissue

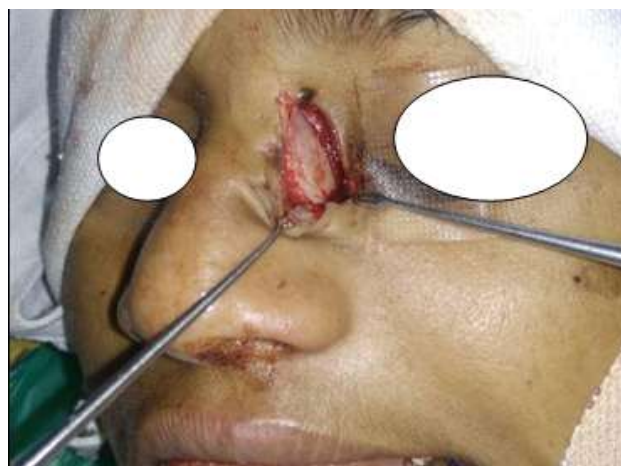

Fig. 8: Showing Piece of septal cartilage which was harvested & used to seal the defect.

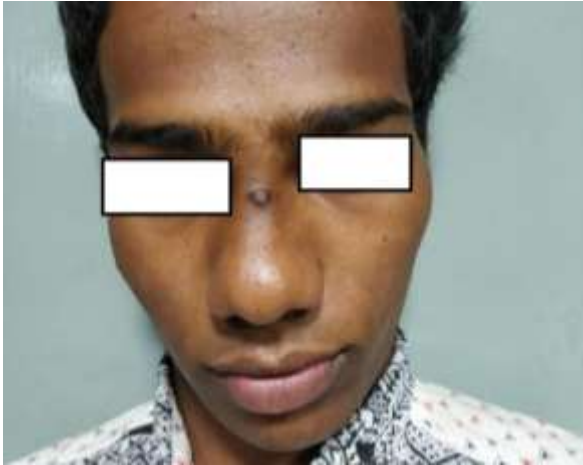

Fig. 9: Showing fistula opening with sebaceous discharge & hair seen in opening

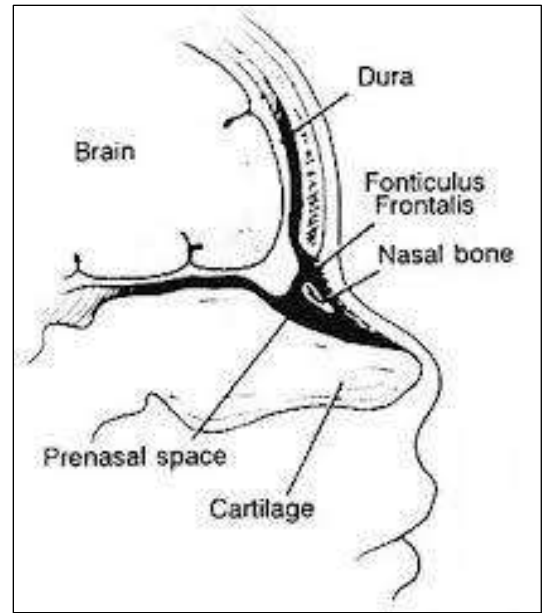


Fig. 12: Showing Prenasal space

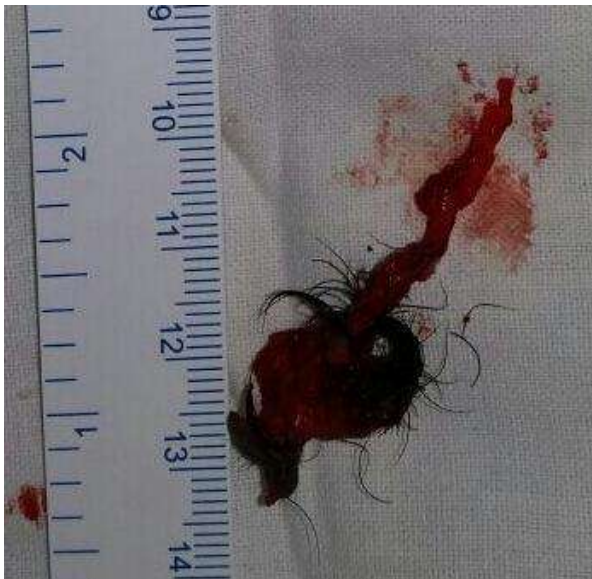

Figure 10- Showing entire length of sinus tract with cyst including surrounding skin was removed which had hairs with sebaceous content in it

Discussion

Nose develops from frontonasal processes & two nasal placodes. During the formation of skull base & nose, mesenchymal structures are formed from several centres which will eventually fuse & ossify. Before their fusion, there are recognized spaces which are important in development of congenital midline nasal masses namely fonticulus frontalis, prenasal space & foramen cecum. Fonticulus frontalis is the space between frontal & nasal bones which eventually fuses with foramen cecum to create separation between intracranial & extracranial structures. Prenasal space is the space between the nasal bone & the nasal capsule which is the precursor of septum & the cartilages (Fig. 12).

Among the midline nasal masses, congenital dermoid cyst & sinuses are very rare anomalies. Differential diagnosis include inflammatory lesions like abscesses; traumatic deformities; benign neoplasms like polyps, Juvenile nasal angiofibromas etc; malignant neoplasms like Rhabdomyosarcomas & congenital masses like dermoid, teratomas & haemangiomas. It accounts for 1-3% of all dermoid in body & 11-12% of dermoid of head & neck region.^{2,4,9,10} The first report about nasofrontal dermoid sinus cyst was published by Bramann in 1890.^{7,10} There are lot of theories about nasofrontal dermoid sinus cyst like sequestration, trilaminary and prenasal. But the most accepted theory is Pratt's Prenasal theory.² He described common embryologic pathway for gliomas, encephalocele & nasofrontal dermoid sinus cyst.^{4,7} Nasal bones are separated from adjacent cartilaginous nasal capsule by prenasal space. This prenasal space extends from brain to nasal tip. During the extension of dura between the unconnected skull bone to nose, dura is related to the dermis of nasal tip. Dura normally separates from nasal dermis during process of ossification. If the bone tissues could not separate the dura from dermis during the ossification, it may

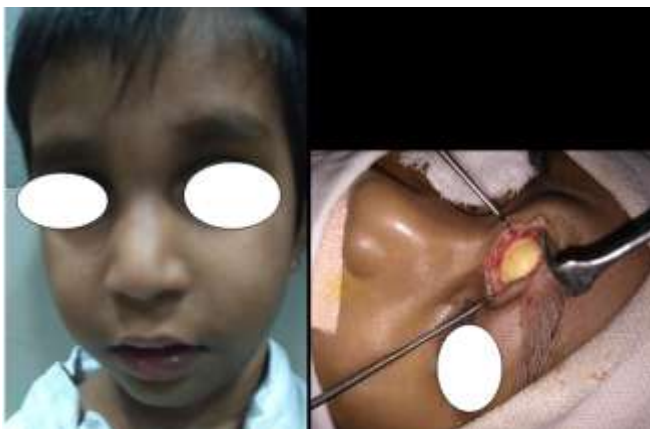

Fig. 11: soft fluctuating swelling over left side of glabella

pull the ectoderm along with it creating persistent ectodermal tract extending from dorsum of nose under the nasal bones or through the nasal bone into the prenasal space and into the cranial cavity through crista galli.⁸ Thus, the anomaly occurs. For the congenital nasal dermoid which originate from ectoderm & mesoderm, the term first used in 1982.^{7,3,4}

Nasofrontal dermoid sinus cysts are usually seen at birth but may get unrecognized till adult life like four of our cases (one patient is of 9 years; two patients are of 15 years each & one patient is 18 years old). In most of the cases of nasofrontal dermoid sinus cyst, diagnoses can be made by three years of age but few cases may get undetected^{4,7} and.¹¹ The oldest patient in literature is 56 years old patient with intracranial extension.⁵ There are some reports about male predominance.⁶ In our study also, we got male predominance with male to female ratio was 5:1. Nasofrontal dermoid sinus cysts are usually sporadic but few familial cases are also reported in literature.^{3,9} All patients in our study were sporadic; no familial association was seen in any of the cases.

Nasofrontal dermoid sinus cysts are usually not associated with any syndrome or other congenital anomalies. In literature there are few studies showing these associations with different ratios varying from 5-41% of patients.⁷ These associated congenital anomalies include craniofacial anomalies, hypertelorism, aural atresia, cleft lip or palate, tracheoesophageal fistula, vertebral column anomaly, dermal cyst of frontal lobe, mental retardation, cardiac & genital anomalies. None of the patients in our study had any associated congenital anomaly.

Nasofrontal dermoid sinus cysts are typically seen as midline masses. It may present as midline nasal pit, fistula or infected mass anywhere from glabella to columella. Sometimes it may present as single cutaneous tract with hair at the opening. It may secrete pus or sebaceous discharge.⁷ Distal third of dorsum is the most common site.^{3,12} In our study, four out of six patients presented with fistulous opening over distal third of dorsum with sebaceous discharge, one of these four patients also had cystic swelling over the dorsum. One patient had soft cystic swelling over the glabella & last patient presented with defect in left nasal bone with childhood history of recurrent burst opened abscess in same area.

These congenital midline nasal masses are important because of their high propensity of intracranial extension.² Hence CT and/or MRI are needed to rule out such extensions^{3,4} and.⁹ In our study, we did CT PNS of every patient which included nasal tip along with CT brain. Only one out of six patients showed soft tissue lesion superior to bony septum with communicating sinus tract to nasal tip with 5.8 mm bony defect in anterior cranial fossa. But no intranasal extension was seen on CT and no intracranial extension was seen intraoperatively though we could locate the defect & manage to close the defect with soft tissue.

Treatment of the nasofrontal dermoid sinus cyst is complete surgical excision.^{3,4,10} Surgery is advised in order to prevent recurrent infection, cosmesis as well as to prevent

intracranial complication. Surgical approach depends upon location & extent of the disease, may be local excision or combined intracranial-extracranial approach. Amongst the local excision, external rhinoplasty approach is preferred¹⁰ as it gives good exposure, good cosmetic result as well as if needed it allows reconstruction of nasal dorsum. In our study, two out of six patients were operated with external rhinoplasty approach with good cosmetic outcome. One out of rest four patient needed external approach with closure of bony defect by septal cartilage graft. In the remaining three patients, elliptical incision taken around fistulous opening & tract is traced & excised completely. In one patient, tract reached till bony defect in ant cranial fossa, defect was sealed with fat & soft tissue. None of our patients showed recurrence till 6 months of follow up.

Conclusion

1. Among the midline nasal masses, congenital dermoid cyst & sinuses are very rare anomalies.
2. Nasofrontal dermoid sinus cysts are usually seen at birth but may get unrecognized till adulthood.
3. These congenital midline nasal masses are important because of their high propensity of intracranial extension. Hence CT and/or MRI is needed to rule out such extensions.
4. Treatment of the Nasofrontal dermoid sinus cyst is complete surgical excision. Surgery is advised in order to prevent recurrent infection, intracranial complication as well as to maintain the cosmesis. Surgical approach depends upon location & extent of the disease, may be local excision or combined intracranial-extracranial approach.
5. Amongst the local excision, external rhinoplasty approach is preferred as it gives good exposure, good cosmetic result as well as if needed it allows reconstruction of nasal dorsum.

Source of Funding

None.

Conflict of interest

None.

References

1. Zapata S, Kerns DB. Nasal Dermoids. *Curr Opin Otolaryngol Head Neck Surg* 2006;14:406-11.
2. Emel CT, Omer TS, Guleser SAO, Hakan K. The management of rare nasal mass- nasal dermoid sinus cyst: Open Rhinoplasty. *Rare Tumours* 2009;1:e40;121-3.
3. Bilkay U, Gundogon H, Ozek C. Nasal Dermoid Sinus Cyst and the Role of Open Rhinoplasty. *Ann Plast Surg* 2001;47:8-14.
4. Post G, McMains KC, Kountakis SE. Adult nasal dermoid sinus cyst. *Am J Otolaryngol* 2005;26:403-5.
5. Hacker DC, Freeman JL. Intracranial extension of nasal dermoid sinus cyst in 56-year-old man. *Head Neck* 1994;16:366-71.
6. Denoyelle F, Ducroz V, Roger G, Gara-bedian EN. Nasal dermoid sinus cysts in children. *Laryngoscope* 1997; 107; 795-800.

7. Hanikeri M, Waterhouse N, Kirkpatrick N, The management of transcranial nasal dermoid sinus cysts. *Br J Plast Surg* 2005;58;1043-50.
8. Tewfik TL, Meyers AD. Congenital malformation of nose. *emedicine Medscape.com/article/837236*
9. Rahbar R, Shah P, Mulliken JB, et al. The presentation & management of nasal dermoid: a 30-year experience. *Arch Otolaryngol Head Neck Surg* 2003; 129; 464-71.
10. Rohrich RJ, Lowe JB, Schwartz MR. The role of open rhinoplasty in the management of nasal dermoid cysts. *Plast Reconstr Surg* 1999;104;2163-70.
11. Yavuzer R, Bier U, Jackson IT. Be careful-it might be nasal dermoid cyst. *Plast Reconstr Surg* 1999;103;2082-3.
12. Sreetharan V, Kangesu I, Sommerlad BC. Atypical Congenital Dermoids of the Face: a 25-year experience. *J Plast Reconstr Aesthet Surg* 2007;60:1025-9.

How to cite this article: Sathe N, Chiplunkar D, Misal P, Sawarkar S, Congenital midline nasal dermoid sinus cyst- our experience, *J Otorhinolaryngol Allied Sci* 2019;2(3):68-73.