

Ramsay hunt syndrome - Type II

Ravneet Ravinder Verma¹, Ravinder Verma^{2*}

¹Ex Senior Resident, ²Senior ENT Consultant Surgeon, ¹All India Institute of Medical Sciences, Delhi, ²Verma Hospital and Research Centre, Gujral Nagar, Jalandhar, Punjab India

*Corresponding Author: Ravinder Verma

Email: verma1999@gmail.com

Abstract

Ramsay Hunt syndrome is the second most common cause of facial palsy.

At least three separate neurological syndromes carry the name of Ramsay Hunt syndrome (RHS), their only connection being that they were all first described by James Ramsay Hunt. Ramsay Hunt syndrome (RHS) type I is a rare and nebulous entity that has alternatively been called dyssynergia cerebellaris myoclonica, dyssynergia cerebellaris progressiva, dentatorubral degeneration, or Ramsay Hunt cerebellar syndrome.

Ramsay Hunt syndrome (RHS) type 2 is a disorder that is caused by the reactivation of preexisting herpes zoster virus in a nerve cell bundle (the geniculate ganglion). Ramsay Hunt syndrome type III, a less commonly referenced condition, and a neuropathy of the deep palmar branch of the ulnar nerve. Ramsay Hunt Syndrome Type II (RHS) is a rare neurological disorder. This syndrome is caused by the varicella zoster virus (VZV), the same virus that causes chickenpox in children and shingles (herpes zoster) in adults. In cases of Ramsay-Hunt syndrome Type II, previously inactive varicella-zoster virus is reactivated and spreads to affect the facial nerves. The classic Ramsay Hunt syndrome, which always develops after a herpetic infection, also can be associated with vertigo, ipsilateral hearing loss, tinnitus, and facial paresis apart from otalgia. Magnetic resonance imaging (MRI) is a new and important tool for use in diagnosing and investigating diseases affecting the facial nerve. In recent gadolinium-DTPA enhanced MRI (GdMRI) studies it has unequivocally been demonstrated that ipsilateral facial nerve, geniculate ganglion, auditory and vestibular nerves, cochlea and vestibule contrast enhancement is present. A case report of Ramsay Hunt syndrome with cochleo-vestibular involvement is reported and role of Gd-MRI is discussed.

Keywords: VZV-Varicella zoster virus, Ramsay hunt syndrome RHS, Facial palsy, GD MRI.

Introduction

At least three separate neurological syndromes carry the name of Ramsay Hunt syndrome (RHS), their only connection being that they were all first described by James Ramsay Hunt. Ramsay Hunt syndrome (RHS) type I is a rare and nebulous entity that has alternatively been called dyssynergia cerebellaris myoclonica, dyssynergia cerebellaris progressiva, dentatorubral degeneration, or Ramsay Hunt cerebellar syndrome. Ramsay Hunt syndrome (RHS) type II also known as Herpes Zoster Oticus is a disorder that is caused by the reactivation of pre-existing herpes zoster virus in a nerve cell bundle (the geniculate ganglion). Ramsay Hunt syndrome type III, a less commonly referenced condition, a neuropathy of the deep palmar branch of the ulnar nerve. The NINDS site incorrectly refers to Herpes zoster oticus as RHS 2, and dyssynergia cerebellaris myoclonica as RHS.¹

Herpes zoster oticus is a common cause of atraumatic facial nerve paralysis of lower motor neuron type. Herpes zoster is a viral disease caused by a specific neurotropic virus varicella zoster, similar to varicella virus, but not identical. Herpes zoster oticus was described by Letulle in 1882 and Körner in 1884, but particularly studied by Ramsay Hunt who reported it as a herpetic disease of ganglion geniculi in 1907.⁹ Acute facial paralysis that occurs in association with herpetic blisters of the skin of the ear canal, auricle, or both is referred to as the Ramsay Hunt syndrome, or herpes zoster oticus. This syndrome also is known as geniculate neuralgia or nervus intermedius neuralgia. Ramsay Hunt syndrome is defined as peripheral facial nerve palsy accompanied by an erythematous

vesicular rash on the ear (zoster oticus) or in the mouth. J Ramsay Hunt, who described various clinical presentations of facial paralysis and rash, also recognized other frequent symptoms and signs such as tinnitus, hearing loss, nausea, vomiting, vertigo, and nystagmus and paralysis of other cranial nerves. He explained these eighth nerve features by the close proximity of the geniculate ganglion to the vestibulocochlear nerve within the bony facial canal.¹³ Magnetic resonance imaging (MRI) is a new and important tool for use in diagnosing and investigating diseases affecting the facial nerve. Recently gadolinium DTPA enhanced MRI (Gd-MRI) studies it has unequivocally been demonstrated that ipsilateral facial nerve contrast enhancement, predominantly in the meatal portion, is present in both Bell's palsy and herpes zoster oticus.¹⁰ Enhancement limited to the geniculate ganglion and to the labyrinthine segment of the facial nerve indicates a good prognosis while a widespread enhancement correlates with a poor prognosis. MRI with contrast may be useful during the acute stage of HZO because it can confirm the diagnosis and can provide prognostic information on the facial function. Treatment started within the first three days from onset of Ramsay Hunt syndrome would most likely not suffer lasting complications. The clinical course is not as favorable as in Bell's paralysis. The therapeutic procedures in Ramsay-Hunt syndrome include administration of conservative therapy and surgical intervention. Facial nerve decompression is indicated in persistent paralyzes or in cases without clear clinical signs of recovery after 6 weeks-2 months from the onset of the disease. The site of decompression is determined by topodiagnostic investigations.⁴

Case Report

Mr. OPS, 59 years old male presented with deep burning pain in and around the right ear for the last 10 days. Tympanic membrane appeared normal with normal mobility. He was put on analgesics thinking it as referred otalgia. After five days, he noticed erythematous vesicular eruptions in the posterior part of the external auditory canal wall. The pain became more intense. Within a week, he developed right-sided facial palsy with vertigo, tinnitus and hearing impairment. He was diagnosed as Herpes Zoster Oticus. Pure tone audiometry showed mild to moderate conductive hearing loss. MRI with T1, T2, T2 flair, DW-EPI and post GAD T1W1 including volume acquisition protocol was done. It demonstrated inflammatory pathology

involving the middle ear and inner ear with inflamed facial nerve in its entire intrapetrous course including the geniculate ganglion. Post contrast enhancement is seen in the semicircular canal. MRI findings were consistent with labyrinthitis, facial neuritis and ganglionitis. Right facial motor nerve conduction study was not recordable. Electromyography of orbicularis oculi and Mentalis revealed normal insertional activity, fibrillation and few small amplitude motor unit action potentials, incomplete recruitment (Fig. 3a and 3b). These findings thus suggestive of axonal involvement of right facial nerve with early reinnervation. He was put on corticosteroids (high doses) and antiviral (Acyclovir) therapy.

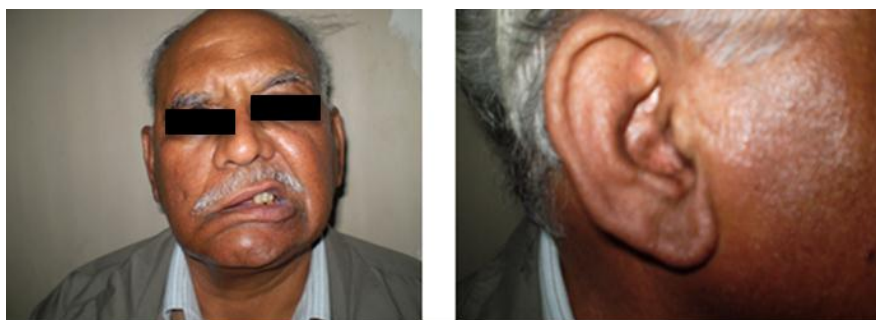

Fig.1: (a) and (b) Showing Right Facial Palsy and eruption in the antitragus area

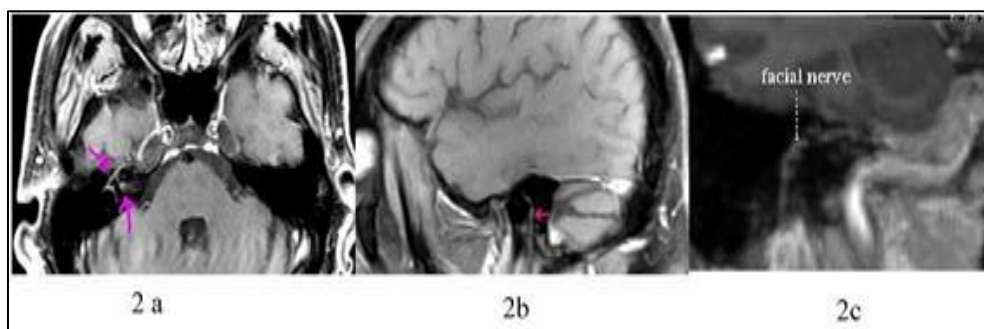


Fig. 2: (a and b): Gd-enhanced MRI showing intrameatal and intrapetrous facial never Fig. 2(c) showing entire intrapetrous course of enhancing facial nerve on oblique MIP.

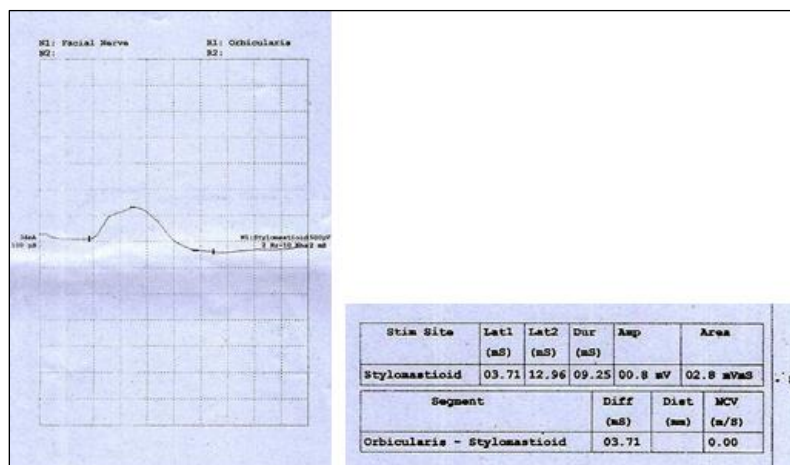


Fig. 3: (a): Nerve conduction study; Fig. 3(b)-Motor Unit Action potential

Discussion

Ramsay Hunt syndrome type II was described first in 1907 by J. Ramsay Hunt in patients who had otalgia associated with cutaneous and mucosal rashes, which he ascribed to infection of the geniculate ganglion by human herpes virus 3 (i.e., varicella-zoster virus [VZV]).

The geniculate ganglion is one of several ganglia of the head and neck. Like others, it is a bilaterally distributed structure, with each side of the face having a geniculate ganglion. It is an "L" shaped collection of fibers and sensory neurons of the facial nerve. It receives fibers from motor, sensory and parasympathetic components of the facial nerve and sends fibers to innervate lacrimal glands, submandibular glands, sublingual glands, tongue, palate, pharynx, external auditory meatus, stapedius, posterior belly of the digastric muscle, stylohyoid muscle and muscles of facial expression. Sensory and parasympathetic inputs are carried into the geniculate ganglion via nervus intermedius. Motor fibers are carried via the facial nerve proper. The greater petrosal nerve with sensory and preganglionic parasympathetic fibres emerges from the anterior aspect of the ganglion.¹⁴ After an attack of chickenpox, the varicella-zoster virus retreats to nerve cells in the body, where it may lie dormant for decades. Like other members of the herpes family (such as the herpes simplex viruses that cause cold sores and genital herpes), the varicella-zoster virus that causes chickenpox never completely leaves the body. Most people don't get chickenpox a second time. However, anyone who has had chickenpox has the potential to develop shingles, because after recovery from chickenpox, the virus settles in the nerve roots.

What triggers the virus to start reproducing later in life? It is still a matter of controversy and lack of knowledge for the researchers. The commonest belief is that it is due to lowered immune system due to aging as 50% of cases occur in patients over 60 years of age. Others at risk, are people with leukemia, lymphoma, or Hodgkin's disease, HIV positive, or have undergone chemotherapy, radiation, transplant surgery with immunosuppression, or treatment with corticosteroids. Moreover, about 5 percent of people with shingles are found to have an underlying cancer.¹⁵ Once activated, the virus travels along the path of a nerve to the skin's surface, where it causes shingles.

Pain may come first. When the migrating virus finally reaches the skin, usually the second to the fifth day after the first symptoms, the virus infects the skin cells and creates a painful, red rash. The rash usually begins as clusters of small bumps that soon develop into fluid-filled blisters (vesicles). In turn, the blisters fill with pus (pustules), break open, and form crusty scabs. In about four or five weeks, the disease runs its course, the scabs drop off, the skin heals, and the pain fades. Most healthy individuals make an uneventful, if not particularly pleasant, recovery. Facial nerve Palsy may appear, in most cases after the rash. Ramsay divided the geniculate herpes into three groups in the original article published in journal of Nervous and mental diseases. The simplest being the herpes of the auricle and external auricle canal. He called it the 'zoster zone' for

geniculate ganglion as comprising of a portion of the tympanic membrane, the external auditory canal, the tragus, antitragus, concha, a part of the helix, antihelix, fossa of antihelix and a strip of the lobule. Secondly, when the auricular herpes is associated with facial palsy due to the pressure of the inflamed ganglion or in some cases, direct extension into the nerve. The third and severest form of the disease is when the acoustic nerve is also involved along the auricular herpes eruption and facial palsy. This form may include tinnitus, deafness, and vertigo. It may be due to the inflammatory process extending to the auditory nerve, which is enveloped in the same sheath as facial nerve in the internal auditory meatus.⁹ Non – neural satellite cells seems to play a major role as hosts for the virus. Reactivation of virus is characterized by infiltration of lymphocytes and round cells in the ganglion and /or its surroundings. Facial Nerve palsy is due to necrotizing inflammation of the ganglion. However, in some cases, it may be due to neuritis and perineuritis of the nerve without involving the ganglion. The viral infection and inflammation may also involve the surrounding structures—the auditory nerve, the vestibular nerve, the modiolus of the cochlea, the organ of corti, the vestibular ganglion, the maculae of utricle and saccule, the auricular muscles and the middle ear mucosa.¹² The classic Ramsay Hunt syndrome always develops after a herpetic infection. The location of the rash varies from patient to patient, as does the area innervated by the nervus intermedius (i.e., sensory portion of CN VII). This area may include the anterior two thirds of the tongue, the soft palate, the external auditory canal, and the pinna.¹ Typically the patient complains of earache, vesicular eruptions in the auricle or its surrounding areas (sometimes in the buccal and oropharyngeal mucosa) and different alterations of VII, VIII, (sometimes V, IX, X) cranial nerves. The rash on the tip of the nose (Hutchinson's sign) is not a favorable feature. It denotes the involvement of ophthalmic nerve. The eye may become affected, possibly causing temporary or permanent blindness. De and Pfleiderer 1999⁵ reported an extreme and unusual variant of this disease with involvement of VIIth, VIIIth, Xth, XIth and XIIth cranial nerves as well as C2–4 sensory dermatomes and profound systemic upset which caused some diagnostic uncertainty. In a ten-year study by Heathfield and Mee 1978,⁷ of the 36 patients, nine had loss of taste, seventeen had vestibular involvement, fourteen patients had deafness, two had sixth nerve palsy and two had post herpetic neuralgia. Role of MRI Magnetic resonance imaging (MRI) especially with Gadolinium enhancement is a new and important tool for use in diagnosing and investigating diseases affecting the facial nerve at an early stage of RHS. Ipsilateral facial nerve contrast enhancement, predominantly in the meatal portion, is present in both Bell's palsy and herpes zoster oticus. Gadolinium does not normally cross the blood-brain barrier but this barrier is broken down in the presence of inflammation or edema. This results in increased signal intensity and enhancement in these areas. Another reason suggested for abnormal enhancement in these situations is venous congestion in the epineurium and perineurium. Kuo

et al 1995,¹¹ reported a case of RHS with left otalgia, rotatory vertigo, sensorineural hearing loss and acute facial nerve palsy. An enhanced magnetic resonance imaging (MRI) scan showed discrete enhancement of the facial and vestibulocochlear nerves in the left internal auditory canal as well as of the labyrinth. Acyclovir started prior to the appearance of any vesicular eruption, full facial function is regained. Three-dimensional fast (or turbo) spin echo (3DFSE) MRI with heavily T2-weighted sections and high resolution three-dimensional Fourier transform (3DFT) MRI, conducted in order to determine whether it is possible to follow the course of the disease and whether MRI and/or Gd-MRI are useful prognostic tools in the early stages of palsy.¹¹ The enhancement limited to the geniculate ganglion and to the labyrinthine segment of the facial nerve indicates a good prognosis while a widespread D enhancement correlates with a poor prognosis. MRI with contrast may be useful during the acute stage of HZO because it can confirm the diagnosis and can provide prognostic information on the facial function.³ The less common findings in RHS are petrositis (Mastoiditis) and demonstrated by T2 weighted MRI as reported by Anton (2007)² and Espay and Bull (2005)⁶ which must be kept in mind. Facial nerve decompression is indicated in persistent paralyses or in cases without clear clinical signs of recovery after 6 weeks-2 months from the onset of the disease. The site of decompression is determined by topodiagnostic investigations. Dankuc et al 2000⁴ performed surgery in two patients and conservative therapy in 3 patients. Electroneurography helps to predict the prognosis of Bell's palsy and Ramsay-Hunt's syndrome. Electroneurography performed between day 7 and 10 for Bell's palsy or day 10 and 14 for herpes zoster oticus does not provide accurate information on the prognosis or recovery rate of the facial paralysis. In order to help define which patients would benefit from surgical decompression and to corroborate the original findings of Fisch and Rubenstein and Gantz undertook a retrospective study in 1999 to assess whether patients with severe degeneration (greater than 90% on ENoG) would benefit from decompression of the facial nerve. In this study, the meatal foramen, labyrinthine segment, geniculate ganglion, and tympanic section were decompressed through a middle cranial fossa approach. This route was chosen because of strong evidence that the conductive block occurs in and around the meatal foramen in 94% of patients (using intraoperative EMG) and that electrical impulse conduction improves after decompression of that area. If the conduction block was not identified during this approach using intraoperative EMG, a transmastoid decompression was added. They reported in a multi-institutional review that 92% of patients who exhibited greater than 90% degeneration on ENoG within 14 days recovered to a HouseBrackmann grade 1 or 2. In patients who were treated only with steroids, only 45% recovered to a House-Brackmann grade 1-2.⁸ Medical management includes Corticosteroids and oral acyclovir along with Vestibular suppressants if vestibular symptoms are severe. As with Bell palsy, care must be taken to prevent

corneal irritation and injury. Temporary relief of otalgia may be achieved by applying a local anesthetic to the trigger point, if in the external auditory canal. Carbamazepine may be helpful, especially in cases of idiopathic geniculate neuralgia. If damage to the nerve is minimal, then a full recovery is usually expected within a few weeks. If damage is more severe, there may not be full recovery -- even after several months. Pain that occurs with the initial outbreak responds to treatment and is limited in duration. Post herpetic pain or post herpetic neuralgia last for months to years after the outbreak, is very miserable and incapacitating. It may be described as agonizing, excruciating, and burning, the pain can result in an inability to perform daily tasks of living, and lead to loss of independence and, ultimately, depression and isolation. Lidoderm patch (transdermal form of lidocaine), transcutaneous electrical nerve stimulation (TENS), and invasive procedures called nerve blocks have been used to provide temporary relief from the PHN. Overall, chances of recovery are better if the treatment is started within 3 days of the onset of the symptoms. Complete recovery is achieved by 70% of patients if treatment is begun at this time. However, when the treatment is delayed more than 3 days, the chances of complete recovery drop to about 50%. Children are more likely to have a complete recovery than adults. Recovery may be complicated if the nerve grows back to the wrong areas (synkinesis) which may cause inappropriate responses, such as tears when laughing or chewing (croc tears). Some people may experience blinking of the eye when talking or chewing food. Dankuc et al 2000⁴ advocate administration of conservative therapy and surgical intervention. Facial nerve decompression is indicated in persistent paralyses or in cases without clear clinical signs of recovery after 6 weeks-2 months from the onset of the disease. The site of decompression is determined by topodiagnostic investigations.

Conclusion

Magnetic resonance imaging (MRI) is a new and important tool for use in diagnosing and investigating diseases affecting the facial nerve. The enhancement limited to the geniculate ganglion and to the labyrinthine segment of the facial nerve indicates a good prognosis while a widespread enhancement correlates with a poor prognosis. In conclusion, MRI with contrast may be useful during the acute stage of HZO because it can confirm the diagnosis and can provide prognostic information on the facial function. The therapeutic procedures in Ramsay-Hunt syndrome include administration of conservative therapy and surgical intervention. Facial nerve decompression is indicated in persistent paralyses or in cases without clear clinical signs of recovery after 6 weeks-2 months from the onset of the disease. The site of decompression is determined by topodiagnostic investigations. Some other people may experience blinking of the eye when talking or chewing food. Conservative therapy and surgical intervention are the main treatment protocol. Facial nerve decompression is indicated in persistent paralyses or in cases without clear

clinical signs of recovery after 6 weeks-2 months from the onset of the disease. The site of decompression is determined by topodiagnostic investigations.

Conflict of Interest: None.

References

1. Awasthi D.; Ramsay hunt syndrome, emedicine.com,2007.
2. Anton, Enrique Less common MRI findings in Ramsay Hunt syndrome type I. (LETTERS TO THE EDITOR) (magnetic resonance imaging) Ear, Nose and Throat Journal, 2007
3. Berrettini S, Bianchi MC, Segnini G, Sellari-Franceschini S, Bruschini P, Montanaro D et al. Herpes zoster oticus: correlations between clinical and MRI findings. *Eur Neurol* 1998;39(1): 26-31.
4. Dankuc D, Milosević D, Komazec Z.() Otogenic herpes zoster-the Ramsay-Hunt syndrome. *Med Pregl* 2000;53(5-6):309-12. PMID: 11089377
5. De S and Pfliederer AG. An extreme and unusual variant of Ramsay Hunt syndrome. *J Laryngology Otology* 1999;113:670-71.
6. Espay AJ, Bull RL. Petrositis in Ramsay Hunt syndrome with multiple cranial neuropathies. *Arch Neurol* 2005;62(11):1774-5.
7. Heathfield KW, Mee AS. Prognosis of the Ramsay Hunt Syndrome; *Br Med J* 1978;343-4.
8. Holsinger FC. (1997) Herpes Zoster Oticus
www.bcm.edu/oto/grand/082197.html (1 of 17)
[5.11.2005 10:42:23].
9. J.Ramsay Hunt. Ramsay Hunt Syndrome- on herpetic inflammation of the Genuiculate Ganglion. A new syndrome and its complications. *J Nerv Mental Dis* 1907;34:73-96 .
10. Jonsson L, Tien R, Engström M, Thuomas KA. Gd-DPTA enhanced MRI in Bell's palsy and herpes zoster oticus: an overview and implications for future studies. *Acta Otolaryngol* 1995;115(5):577-84 PMID: 8928627
11. Kuo MJ, Drago PC, Proops DW, Chavda SV. Early diagnosis and treatment of Ramsay Hunt syndrome: the role of magnetic resonance imaging. *J Laryngol Otol* 1995;109(8):777-80
12. Pau HW. (Rostock)-(Herpes) Zoster Oticus—in Herpes Zoster, Recent aspects of Diagnosis and Control, Monogr. Virol. Ed by Gross G. and Doerr HW. *Published by Karger* 2006;26(47):47-5713.
13. Sweeney CJ, Gilden DH(2001). Ramsay hunt syndrome. *J Neurol Neurosurg Psychiatry* 2001; 71(2):14
14. Yanagida M, Ushiro K, Yamashita T, Kumazawa T, Katoh T. Enhanced MRI in patients with Ramsay-Hunt's syndrome. *Acta Otolaryngol Suppl* 1993;500:58-61
15. Zamula E. Shingles: An Unwelcome Encore FDA consumer magazine (May-June)2001.

How to cite this article: Verma RR, Verma R. Ramsay hunt syndrome - Type II. *J Otorhinolaryngol Allied Sci* 2019;2(2):53-7.