

Content available at: <https://www.ipinnovative.com/open-access-journals>

IP Journal of Otorhinolaryngology and Allied Science

Journal homepage: <https://www.joas.co.in/>

## Case Report

# Massive mandibular ameloblastoma masquerading malignancy: A unique case

Shruti Jha<sup>1</sup>, Mani Mala<sup>1</sup>, Amod Kumar<sup>2</sup>, Sanjeet Goit<sup>1</sup>, Rakesh Kumar Singh<sup>1\*</sup>

<sup>1</sup>Dept. of ENT, Indira Gandhi Institute of Medical Sciences, Patna, Bihar, India

<sup>2</sup>Dept. of Pathology, Nalanda Medical College, Patna, Bihar, India



### ARTICLE INFO

#### Article history:

Received 12-03-2024

Accepted 18-04-2024

Available online 01-05-2024

#### Keywords:

Ameloblastoma

Bony swelling

Mandible

### ABSTRACT

Ameloblastomas are odontogenic tumours that arise from the maxilla and mandible. They are mostly benign but can seldom turn malignant. Their low incidence (<1-3%) and ambiguous presentation can often pose a diagnostic dilemma for the clinician. They are mostly diagnosed with the help of contrast-enhanced computed tomography scans and confirmed by characteristic findings on histopathological examination. We present a case of a 14-year-old boy presenting with a firm to hard external swelling on the right side of his face and extensive intra-oral mass, which showed features of a bony malignancy but was subsequently diagnosed with ameloblastoma.

This is an Open Access (OA) journal, and articles are distributed under the terms of the [Creative Commons Attribution-NonCommercial-ShareAlike 4.0 License](https://creativecommons.org/licenses/by-nc-sa/4.0/), which allows others to remix, tweak, and build upon the work non-commercially, as long as appropriate credit is given and the new creations are licensed under the identical terms.

For reprints contact: [reprint@ipinnovative.com](mailto:reprint@ipinnovative.com)

## 1. Introduction

Ameloblastoma, synonymous with adamantinoma, is an odontogenic tumour from the dental lamina.<sup>1</sup> They mainly arise from the maxilla and mandible, with the posterior mandible being a favourable location. They are mostly benign, slow-growing, and painless bony masses that rarely show an aggressive course. Ameloblastomas are caused by mutations in genes belonging to MAPK (the mitogen activated protein kinase) in most cases, BRAF V600E being commonly associated in about 46 to 90% of affected individuals. The other mutations which have been identified are EGFR PTEN, PIK3CA, and TP53, which occur concurrently with BRAF V600E, and some others, like KRAS, HRAS, and SMO, which might not be associated with B. Mutations in chromosome number 22, have also been described this.<sup>2</sup>

These lesions are solid or multicystic, uni-cystic, extraosseous or peripheral, and desmoplastic.<sup>3</sup> On radiological examination, they most commonly involve the

ramus of the mandible with thinning of the inferior border and are characterized by a soap bubble appearance.<sup>4</sup> They appear as multilocular radiolucent lesions that are mostly well-demarcated and defined with scalloped margins. They also may show buccal and lingual cortical plate expansion and blunting and displacement of the adjacent teeth.

Osteosarcoma, keratocystic odontogenic tumour and giant cell granuloma pose as possible differential diagnoses.<sup>5</sup> Osteosarcomas with significant bony destruction, sunray appearance and a history of addiction can mislead the clinician regarding the correct treatment plan and possible diagnosis. Ameloblastomas can seldom metastasize in less than 2% of cases but are mostly cured by en-block surgical resection, which remains the gold standard of the treatment protocol.<sup>6</sup>

We report a case of an adolescent 14-year-old male presenting with an intra-oral mass and significant bone involvement and destruction. The most staggering and astonishing aspect was the tumour masquerading as a bony malignancy clinically as well as radiologically, which constituted a pre-operative and intraoperative diagnostic dilemma regarding the correct line of treatment and

\* Corresponding author.

E-mail address: [rkent5@gmail.com](mailto:rkent5@gmail.com) (R. K. Singh).

subsequent post-operative course of action.

Our sincere effort in this case report is to establish ameloblastoma as an effective differential diagnosis in odontogenic tumours with aggressive clinical presentation and inconclusive history and radiological findings.

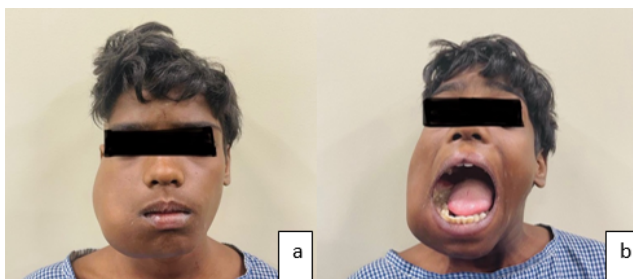## 2. Case Report

A 14-year-old male patient presented to the ENT OPD of our tertiary care centre with complaints of gradually progressive painful swelling over the right side of the cheek and intraoral mass for the last 1 year. For this, he undertook consultations at multiple centres where he got conservative treatment and indigenous medicines with unsatisfactory outcomes. The mass attained huge intra-oral and extraoral size, completely disfiguring his face and producing feeding difficulties. He also experienced the extrusion of a bit of fleshy tissue and reported occasional oral bleeding.

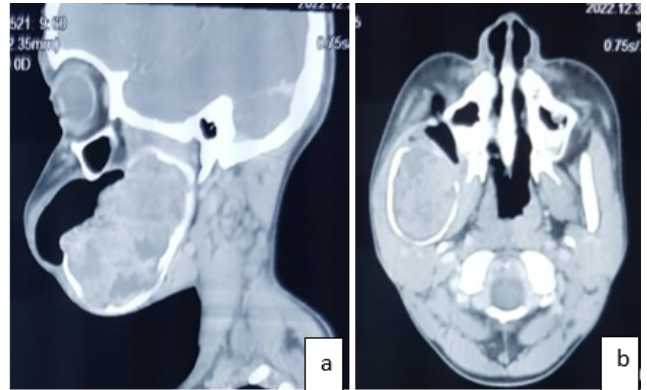
On examination, the swelling was extended from the right pre-auricular region to the midline of the face and from the right cheek up to the level of the hyoid. It was variable in consistency and seemed to originate from the mandible. The skin over the mass was tense without any vascular prominence. The temperature over the lesion was similar to other body areas, and there was no compressibility or fluctuation. Intra-oral examination showed the right side of the mouth full of fleshy, pinkish friable intraoral mass extending from the canine to the retromolar region of the right side. The mass was coated with slough and did not bleed on touch. (Figure 1a,b) The neck examination showed a node neck measuring 1.5 X 1.5 cm at level 2, which was mobile and non-tender. Cranial nerves were normal on examination, and the patient had no other palpable swelling elsewhere in the body.

With the clinical suspicion of malignancy, the CECT scan was advised that showed.

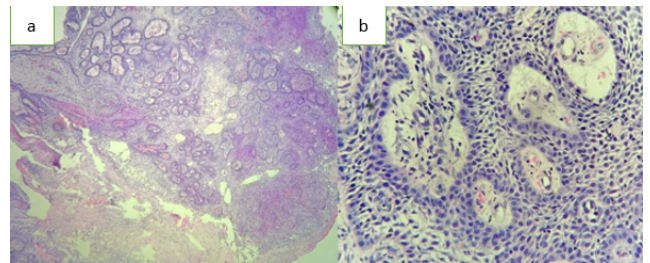
(Figure 2 a,b) 3.8 X 7 X 7.8 cm large expansile swelling involving body, ramus and coronoid process of right hemi mandible causing significant cortical thinning and focal discontinuity of outer and inner cortex of mandible.



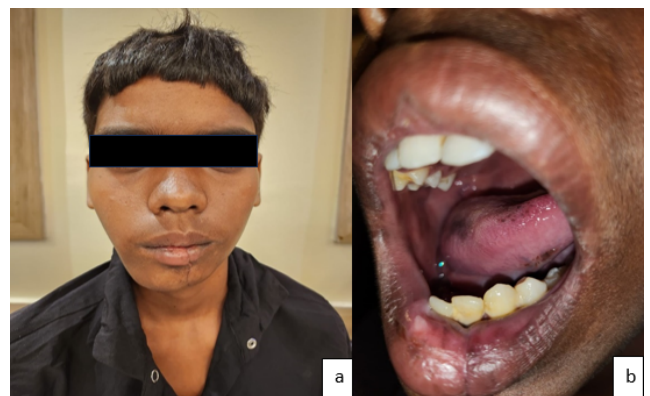**Figure 1: a,b:** Showing the bony swelling on the right side of the face and its intraoral extent.



**Figure 2: a,b:** CECT oral cavity and mandible axial and sagittal section showing homogenous large expansile lesion involving the body, ramus and coronoid process of the mandible.



**Figure 3: a:** 10 X magnification, **b:** 40 X magnification showed islands and cords of columnar cells at the basal region with peripheral palisading. The central portion showed oval and inflammatory cells, blood vessels, and haemorrhage.



**Figure 4: a,b:** Postoperative pictures showing complete resolution of mass and healing.

A pre-operative FNAC was performed, which established a tentative diagnosis of ameloblastoma. A differential diagnosis of suspected bony malignancy was made, and en-block surgical resection with hemi mandibulectomy and supra-omohyoid neck dissection was planned. Necessary consents were taken, a pre-anesthetic checkup was done, and the patient, with all risks explained, was posted for surgery. Histopathological examination of the resected specimen showed the tumour composed of cords and sheets of odontogenic epithelium in a fibro-myxoid connective tissue with peripheral palisading and cystic changes. No atypia or evidence of malignancy was present, and the patient was diagnosed with ameloblastoma. (Figure 3 a,b)

Postoperative healing was adequate, and the patient was discharged on day 7 with subsequent follow-ups, revealing a complete cure and disease-free status. (Figure 4a,b)

### 3. Discussion

Ameloblastomas can be nefariously challenging to diagnose because of their ambiguous clinical presentation. They usually occur in patients in their third decade of life, though they can present at any age. The progressive facial deformity can lead to the tumour often attaining massive proportions due to lack of timely medical intervention, which is very common in developing countries like ours. The delay in diagnosis is exacerbated by a vague presentation and low prevalence, which often lead to the clinician ruling in ameloblastomas very late in the course of treatment and lead to wastage of crucial time. Due to identical histology, Benign ameloblastomas can be extremely difficult to differentiate from malignant ameloblastic carcinomas, malignant ameloblastomas and other bony malignancies.<sup>7</sup> The metastasizing variant to the lungs usually occurs decades after the first treatment and can often be misdiagnosed as primary squamous cell carcinoma of the lung. Thus, it stresses the importance of long-term follow-up in patients diagnosed with the disease.<sup>8</sup>

In our case, diagnostic difficulties were due to the patient's younger age of presentation, the location of the tumour being the anterior mandible, a history of progression, pain, paraesthesia of the lower lip, and ambiguous radiological findings, which were more in favour of an aggressive malignancy such as osteosarcoma rather than a benign entity like ameloblastoma.

The main modality of treatment, just as was done in our case, remains wide resections with 2-3 cm margins to ensure removal of all cysts and prevent recurrence,<sup>9</sup> which is a staggering 13-15% despite resections and 90-100% after curettage with reconstruction in extensive cases also proving to be a significant challenge.<sup>10</sup>

### 4. Conclusion

Our endeavor in publishing this case report is to reiterate the significance of establishing ameloblastomas as an essential differential in jaw pathologies despite ambiguous and aggressive misleading clinical presentations and to ensure timely treatment and cure for all patients.

### 5. Source of Funding

No funding sources.

### 6. Conflict of Interest

None.

### 7. Acknowledgement

We want to thank the administration of the Indira Gandhi Institute of Medical Sciences for supporting the publication of this manuscript.

### References

1. Suma MS, Sundaresh KJ, Shruthy R, Mallikarjuna R. Ameloblastoma: an aggressive lesion of the mandible. *BMJ Case Rep.* 2013;p. bcr2013200483. doi:10.1136/bcr-2013-200483.
2. Marín C, Niklander SE, Martínez-Flores R. Genetic Profile of Adenomatoid Odontogenic Tumor and Ameloblastoma. A Systematic Review. *René Martínez-Flores.* 2021;p. 767474. doi:10.3389/froh.2021.767474.
3. Hertog D, Bloemena E, Aartman IH, Van-Der-Waal I. Histopathology of ameloblastoma of the jaws; some critical observations based on a 40 years single institution experience. *Med Oral Patol Oral Cir Bucal.* 2012;17(1):76–82.
4. Arijji Y, Morita M, Katsumata A, Sugita Y, Naitoh M, Goto M, et al. Imaging features contributing to the diagnosis of ameloblastomas and keratocystic odontogenic tumours: logistic regression analysis. *Dentomaxillofac Radiol.* 2011;40(3):133–40.
5. Vijayan S, Steward-Tharp SM, Melo SS, Allareddy V, Anamali-Allareddy S. A unique case of ameloblastoma mimicking a malignant lesion. *Oral Surg, Oral Med, Oral Pathol Oral Radiol.* 2019;127(1):48. doi:10.1016/j.oooo.2018.07.048.
6. Jayaraj G, Sherlin HJ, Ramani P, Premkumar P, Natesan A, Ramasubramanian A, et al. Metastasizing Ameloblastoma - a perennial pathological enigma? Report of a case and review of literature. *J Craniomaxillofac Surg.* 2014;42(6):772–9.
7. Ram H, Mohammad S, Husain N, Gupta PN. Ameloblastic carcinoma. *J Maxillofac Oral Surg.* 2010;9(4):415–9.
8. Yun JS, Kim DW, Kim SS, Choi YD, Song SY, Na KJ, et al. Metastatic pulmonary ameloblastoma misdiagnosed as primary squamous cell carcinoma preoperatively. *Korean J Thorac Cardiovasc Surg.* 2014;47(1):63–5.
9. Aramanadka C, Kamath AT, Kudva A. Recurrent Ameloblastoma: A Surgical Challenge. *Case Rep Dent.* 2018;p. 8271205. doi:10.1155/2018/8271205.
10. Saravanan B, Balaji J, Rohini T, Kumar A. Recurrent ameloblastoma 24 years after hemimandibulectomy: A case report and literature review. *Indian J Dent Res.* 2019;30(6):960–3.

**Author biography**

**Shruti Jha**, Senior Resident

**Mani Mala**, Junior Resident

**Amod Kumar**, Assistant Professor

**Sanjeet Goit**, Senior Resident

**Rakesh Kumar Singh**, Professor

**Cite this article:** Jha S, Mala M, Kumar A, Goit S, Singh RK. Massive mandibular ameloblastoma masquerading malignancy: A unique case. *IP J Otorhinolaryngol Allied Sci* 2024;7(1):16-19.