

Content available at: <https://www.ipinnovative.com/open-access-journals>

IP Journal of Otorhinolaryngology and Allied Science

Journal homepage: <https://www.joas.co.in/>

## Case Report

# An unusual foreign body in the trachea: A broken PVC tracheostomy tube

Amarjeet Kumar<sup>1</sup>, Manish Gupta<sup>1,\*</sup>, Kiran J Thomas<sup>1</sup>, Akanksha Gupta<sup>2</sup>

<sup>1</sup>Dept. of ENT, Maharishi Markandeshwar Institute of Medical Sciences and Research, Ambala, Haryana, India

<sup>2</sup>Dept. of ENT, School of Medical Science and Research, Sharda University, Greater Noida, Uttar Pradesh, India



### ARTICLE INFO

#### Article history:

Received 22-07-2022

Accepted 30-08-2022

Available online 07-10-2022

#### Keywords:

Tracheostomy tube

Airway

Foreign body

Bronchoscopy

Equipment failure

Respiratory aspiration

### ABSTRACT

In patients with upper airway obstruction and on long-term ventilatory support, tracheostomy is often needed. One rare complication of the same is fracture and aspiration of distal portion into the lower airway, mainly seen in metallic tubes. We report a very rare case, where aspiration of fractured PVC tracheostomy tube occurred, which was successfully removed by rigid bronchoscopy. The etiology and prevention measures are also being reviewed.

This is an Open Access (OA) journal, and articles are distributed under the terms of the [Creative Commons Attribution-NonCommercial-ShareAlike 4.0 License](https://creativecommons.org/licenses/by-nc-sa/4.0/), which allows others to remix, tweak, and build upon the work non-commercially, as long as appropriate credit is given and the new creations are licensed under the identical terms.

For reprints contact: [reprint@ipinnovative.com](mailto:reprint@ipinnovative.com)

## 1. Introduction

The word tracheotomy derives from two Ancient Greek words: the word trachea (Greek tracheiaogy) and the word stoma (Greek stoma) meaning “mouth,” and refers to the making of a semi-permanent or permanent opening and placing a tracheostomy tube to provide appropriate ventilation for patient.<sup>1</sup> It is a common airway procedure for life support.

Although the procedure is safe with a mortality rate of less than 5%,<sup>2</sup> morbid complications which may occur are categorized into early and late. Early complications are hemorrhage, pneumothorax, tracheostomy tube obstruction, and infection at the stoma site. While the stomal granulations, stenosis, innominate vessel damage, and tracheoesophageal fistula are common late complications.<sup>3</sup> The complication with the lower airway foreign body may result from a fracture of the tube. Metallic tracheostomy tubes were often used in patients in the past. The tubes were known to undergo corrosion, fracture, and dislodgement

of distal segments in the lower airway. Few case reports highlight this drawback of prolonged usage of metallic tubes, but PVC tubes are less prone to fracture.

Here, we report an unusual case of a 45-year-old male with a broken large piece of PVC tracheostomy tube as a foreign body in the trachea & right main bronchus. This case highlights that even PVC tubes may undergo wear and tear with prolonged usage, which makes them brittle.

## 2. Case Summary

A 45-year male came to our hospital emergency with complaints of breathlessness for 7 hours following aspiration of fractured PVC tracheostomy tube after a fall in the field. The patient was tracheotomized 27 years back with a history of laryngeal edema following inhalation of toxic gas while cleaning a well. The patient failed to follow up with an ENT specialist for a long time and used to clean the tube by himself with no supervision of the health care worker. A few years back due to financial problems, the patient refabricated and stitched the flanges of his tracheostomy tube and was continuously using the same

\* Corresponding author.

E-mail address: [manishgupta1217@gmail.com](mailto:manishgupta1217@gmail.com) (M. Gupta).

tube for the last 6 years.

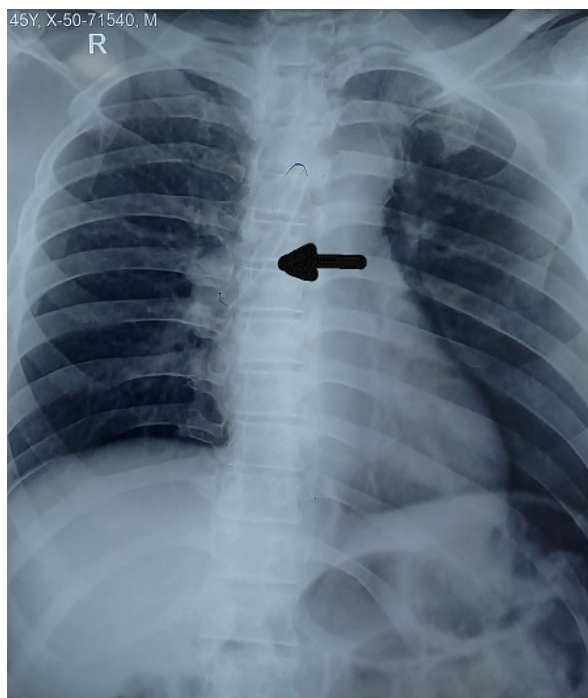
The patient presented to emergency with mild productive cough with no respiratory distress/stridor. On examination, the patient was having tachypnea and maintaining saturation of 94% on room air & his other hemodynamic parameters were stable. B/L Chest was clear on auscultation.

Postoperatively, the patient was hemodynamically stable. The evaluation of the upper airway tract was normal with no signs of residual disease/edema or any other pathology obstructing the upper airway, thus we planned for decannulation and surgical closure was done after 2 days.

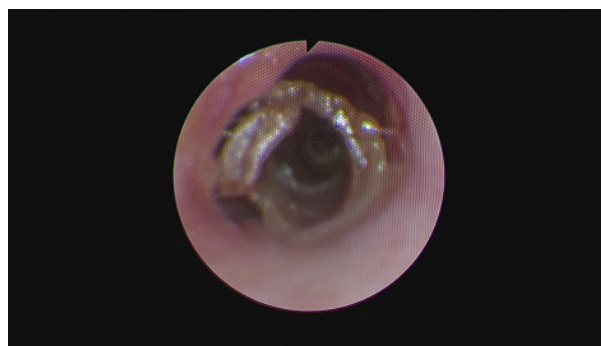### 3. Discussion

There have been a variety of foreign bodies, being reported in the tracheobronchial tree. A fractured tracheostomy tube is rare, further that too of PVC is even rarer. A tracheostomy tube broken and migrated in the distal airway can be a life-threatening emergency requiring precise and prompt management.

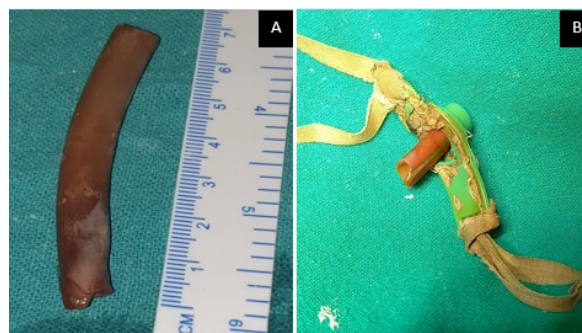
The first case published in the medical literature of a fractured tracheostomy tube was in 1960.<sup>1</sup> Gupta in 1987 reported a series of fractured tracheostomy tubes, distally migrated in 9 cases.<sup>3</sup> The most common reported fracture site, in a metallic tube, is at the junction between the tube and the neck plate.<sup>4</sup> The most common etiology was the corrosion with saliva, over prolonged usage. The commonest site of displaced tube lodgement was the trachea and the right main bronchus.<sup>5</sup>



**Fig. 1:** Chest X-ray PA view showing broken tracheostomy tube in the right main bronchus and distal trachea.



**Fig. 2:** The endoscopic view of broken and distally migrated PVC tracheostomy tube- note the ragged margin.



**Fig. 3:** A: & B: The picture showing both the distal and proximal fragment of the broken PVC tube- note the color change, ragged margin at the breakpoint, and the repaired flanges.

Chest X-ray PA view clinches the diagnosis in most cases, with such a large foreign body.<sup>6</sup> In doubtful cases, computed tomography with virtual bronchoscopy is helpful.<sup>6,7</sup>

A foreign body in an airway is an emergency, requiring prompt action. In our case, since the distally migrated PVC tube was hollow, the patient had no respiratory distress or lung field changes. The small foreign body may be retrieved with the small jaw forceps of the fiberoptic bronchoscope, but the large tube, as in our case required rigid bronchoscopy and stout forceps to grasp and pull the same out. Also in our case, the presence of tracheostome, allowed bronchoscope to be introduced from it, making the task more direct and easier.

### 4. Conclusion

Patients with tracheostomy tubes should be educated about this potential complication. The tubes should be periodically checked and old worn out replaced, at the earliest. Bronchoscopy via tracheostome is easy, quick, and carries fewer complications.

## 5. Declaration

The authors certify that they have obtained all appropriate patient consent forms. In the form, the patient(s) has/have given his/her/their consent for his/her/their images and other clinical information to be reported in the journal. The patients understand that their names and initials will not be published and due efforts will be made to conceal their identity, but anonymity cannot be guaranteed.

## 6. Data Availability Statement

Previously reported [case reports, case series, and review articles as mentioned in references] data were used to support this study and are available at [DOI]. These prior studies (and datasets) are cited at relevant places within the text as references (#-#)

## 7. Ethics Statement

All procedures performed in this study, involved human participants and were strictly in accordance with the ethical standards of the institutional and/or national research committee and with the 1964 Helsinki declaration and its later amendments or comparable ethical standards.

## 8. Source of Funding

None.


## 9. Conflict of Interest

None.

## References

1. Bassoe HH, Boe J. Broken tracheotomy tube as a foreign body. *Lancet*. 1960;2016(1):90890–4.
2. Stauffer JL, Olson DE, Petty TL. Complications and consequences of endotracheal intubation and tracheotomy. A prospective study of 150 critically ill adult patients. *Am J Med*. 1981;70(1):90413–20.
3. Gupta SC, Ahluwalia H. Fractured tracheostomy tube: An overlooked foreign body. *J Laryngol Otol*. 1996;110(11):1069–71.
4. Piromchai P, Lertchanaruengrit P, Vatanasapt P, Ratanaanekchai T, Thanaviratananich S. Fractured metallic tracheostomy tube in a child: A case report and review of the literature. *J Med Case Reports*. 2010;2(4):234.
5. Alqudehy ZA, Alnufaily YK. Fractured tracheostomy tube in the tracheobronchial tree of a child: Case report and literature review. *J Otolaryngol Head Neck Surg*. 2010;39(6):70–3.
6. White AC, Kher S, Connor O. When to change a tracheostomy tube. *Respir Care*. 2010;55(8):1069–75.
7. Krishnamurthy A, Vijayalakshmi R. Broken tracheostomy tube: A fractured mandate. *J Emerg Trauma Shock*. 2012;5(1):97–9.

## Author biography

**Amarjeet Kumar**, Post Graduate Student  <https://orcid.org/0000-0002-6417-0776>

**Manish Gupta**, Professor  <https://orcid.org/0000-0001-7784-308X>

**Kiran J Thomas**, Senior Resident  <https://orcid.org/0000-0001-8702-0896>

**Akanksha Gupta**, Student  <https://orcid.org/0000-0002-0566-0601>

**Cite this article:** Kumar A, Gupta M, Thomas KJ, Gupta A. An unusual foreign body in the trachea: A broken PVC tracheostomy tube. *IP J Otorhinolaryngol Allied Sci* 2022;5(3):91-93.