

Content available at: <https://www.ipinnovative.com/open-access-journals>

IP Journal of Otorhinolaryngology and Allied Science

Journal homepage: <https://www.joas.co.in/>

Original Research Article

A study to evaluate the change in management plan of chronic otitis media (mucosal) after cone beam computed tomography

Shantha Nitin¹, Renu Rajguru^{2,*}, Dilip Raghavan³¹159 GH, Ferozpur, Punjab, India²Dept. of ENT, 15 Air Force Hospital, Jaisalmer, Rajasthan, India³Office of DGAFMS, New Delhi, India

ARTICLE INFO

Article history:

Received 30-07-2022

Accepted 12-08-2022

Available online 07-10-2022

Keywords:

Cone Beam Computed Tomography
Chronic Otitis Media (Mucosal)
management plan

ABSTRACT

Introduction: Imaging of temporal bone helps the Otologists in preoperative surgical planning in ear surgery. Cone Beam Computed Tomography (CBCT) has much higher spatial resolution and clarity as compared to conventional X-Ray and much lower radiation exposure as compared to HRCT Temporal Bones.

Aim: To evaluate the change in management plan of Chronic Otitis Media (Mucosal) after CBCT. Also to determine the sensitivity and specificity of the CBCT findings by comparing with intra operative findings in the study participants.

Materials and Methods: We conducted an observational descriptive study in the ENT Department of an academic Tertiary care hospital from October 2017 to October 2019. We included 95 patients whose management plan before CBCT was compared with the plan after CBCT and the percentage of cases undergoing a change in the management after CBCT was determined. The correlation of CBCT findings and intra operative findings in terms of specificity and sensitivity was also statistically calculated.

Results: Subsequent to imaging, the management plan was changed in only 4 patients which was statistically non-significant. CBCT showed a 100% sensitivity, specificity, positive predictive value and negative predictive value to detect pneumatisation of the Mastoid, high jugular bulb and low-lying dura. The sensitivity to detect ossicular erosion was 98.9%.

Conclusion: Thorough clinical examination is the most important factor in decision making in patients with Chronic Otitis Media (Mucosal) and management plan remains unchanged after imaging. Though thorough clinical examination remains the gold standard in making a management plan of patients with Chronic Otitis Media (Mucosal), CBCT with its available details and minimal radiation helped to minimise intraoperative inadvertent injuries which might result due to normal anatomic variations like low lying dura, forward lying sinus, contracted mastoid cavity etc.

This is an Open Access (OA) journal, and articles are distributed under the terms of the [Creative Commons Attribution-NonCommercial-ShareAlike 4.0 License](https://creativecommons.org/licenses/by-nc-sa/4.0/), which allows others to remix, tweak, and build upon the work non-commercially, as long as appropriate credit is given and the new creations are licensed under the identical terms.

For reprints contact: reprint@ipinnovative.com

1. Introduction

Management options for Chronic Otitis Media (Mucosal) are surgery, hearing aids or no treatment. The aim of middle ear surgery in cases of Chronic Otitis Media (COM) is to give a dry ear to the patient and reduce their

hearing disability. Various surgical options available for COM (Mucosal) are Myringoplasty, Tympanoplasty with or without ossiculoplasty and with or without Cortical Mastoidectomy.¹ Because of availability of these varied options which are guided by extent of disease, ossicular status, anatomical variations and presence or absence of complications, prior knowledge of the exact surgery which needs to be performed in a particular patient would help the

* Corresponding author.

E-mail address: renurajguru@yahoo.com (R. Rajguru).

Otologists in preoperative surgical planning.

Clinical examination of a case of COM can help in visualisation of the disease and ossicular status only to a limited extent, but imaging of temporal bone can help to obtain excellent preoperative visualisation of ossicular status, anatomical variations and extent of the disease and also assist in assessing any asymptomatic complications. Hence the role of imaging in planning the surgeries in cases of COM cannot be over emphasized.^{2,3}

Conventional imaging technique for COM is radiograph of mastoid (Schuller's view), which gives very limited information. As the role of preoperative CT in COM (Squamous) is of immense importance and well established, it has been suggested that it could be extrapolated to COM (Mucosal) for evaluating the above mentioned pathological entities and anatomical variations, thereby allowing accurate pre-operative assessment and management planning of intraoperative steps.⁴⁻⁷

High Resolution Computerised Tomography (HRCT) scan of the Temporal Bone provides excellent information but is associated with high level of radiation exposure. In the last few years an alternative has been found, namely Cone Beam Computed Tomography (CBCT), which, like HRCT is based on the application of X-Rays.^{8,9} CBCT offers a good spatial resolution and detailed reconstruction with a significantly lower irradiation in comparison with HRCT and is being routinely used in for minor dental and medical conditions.^{2,3,10} CBCT is a latest upcoming technology where imaging is accomplished by using a rotating gantry to which an X-Ray source and detector are fixed. A divergent pyramidal or cone-shaped source of ionizing radiation is directed through the middle of the area of interest onto an X-Ray detector on the opposite side. The imaging can be done in supine, sitting or an erect posture. Computed Tomography Dose Index (CTDI) of a CT scan of middle ear is around 170 mGy compared to 15-30 mGy for Cone Beam CT.^{9,11-16} Another advantage is that CBCT is very fast, usually taking between 9-18 seconds, and is available in an OPD setting, thus more convenient. Furthermore, it is an open device, so it can be done even in claustrophobic and anxious persons.²

The aim of this study was to determine any change in management plan of evaluated cases of COM (Mucosal) post CBCT as assessed by the treating ENT Surgeon. Our secondary objective was to determine the sensitivity and specificity of the CBCT findings as compared to the intra operative findings in the study participants.

2. Materials and Methods

This was an observational descriptive study conducted in the Department of Otorhinolaryngology & Head and Neck Surgery of an academic tertiary care hospital from October 2017 to October 2019.

As ossicular erosion is the most important parameter in changing the management plan in cases of COM (Mucosal),

the sample size was calculated on the basis of prevalence of ossicular erosion, which is reported to be around 13.9%.⁴ Assuming this prevalence, with 95% confidence interval and deviation of 5%, the sample size was calculated as $95. n = 1.96 \times p \times (1-p) \div (0.05)^2$.

The clearance from Institutional Ethics Committee was obtained on 16 Nov 2017. All diagnosed cases of COM (Mucosal) of more than 16 years of age reporting to the ENT outpatient department and willing to participate were included in this study. Cases of COM Squamous disease, those with presence of overt complications of COM or cases requiring revision surgery for COM were excluded from this study.

The participants were counselled about their participation in the study and informed consent was taken. After detailed history taking, patients underwent complete systemic and ENT examination including otoscopic, otomicroscopic examination and audiological evaluation, and these formed the basis of a tentative management plan by an ENT surgeon with at least 10 years of experience in this Tertiary Care Hospital. This plan was recorded.

The patients then underwent CBCT Temporal Bone using New Tom CEFLA SC, SN 70820658 machine made in Imola (BO), Italy. The extent of disease, status of the ossicular chain, anatomical variations and presence of complications if any were studied. The CBCT findings were discussed with an experienced Radiologist and the management plan was then revised if needed and recorded.

Details of management plan before CBCT were compared with the plan after CBCT. The percentage of cases undergoing a change in the management after CBCT was determined. The nature of change in the management plan was also noted. The correlation of CBCT findings and intra operative findings in terms of specificity and sensitivity was statistically calculated using Mc Nemar's test.

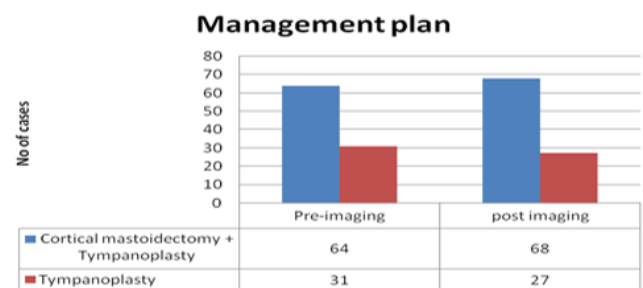

Fig. 1: Comparative bar chart of two types of surgeries performed in the study population

3. Observation & Results

Our study evaluated patients with COM (Mucosal) and studied the utility of CBCT as a tool to assess change in

Table 2: Table showing comparison of CBCT findings and Intra operative findings

Pneumatisation	CBCT findings		Intra op findings	
	Frequency	Percentage (%)	Frequency	Percentage (%)
Sclerosed	68	71.6	68	71.6
Pneumatised	27	28.4	27	28.4
High Jugular Bulb				
Present	15	15.8	15	15.8
Absent	80	84.2	80	84.2
Low-lying Dura				
Present	14	14.7	14	14.7
Absent	81	85.3	81	85.3
Ossicular Erosion				
Present	0	0	1	1.1
Absent	95	100	94	98.9

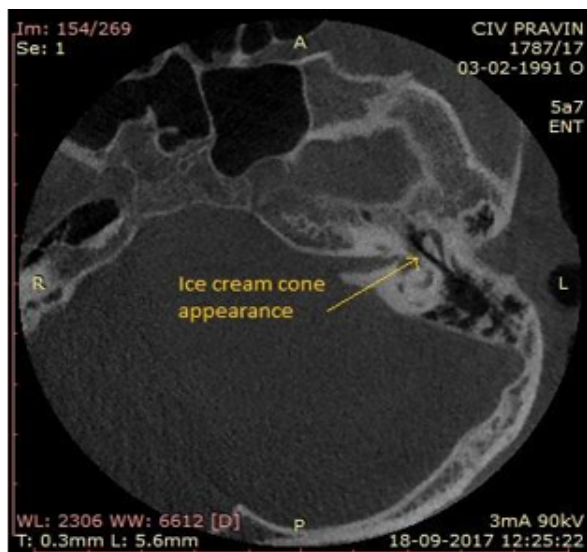


Fig. 2: Ice cream cone appearance of head of malleus and body of incus

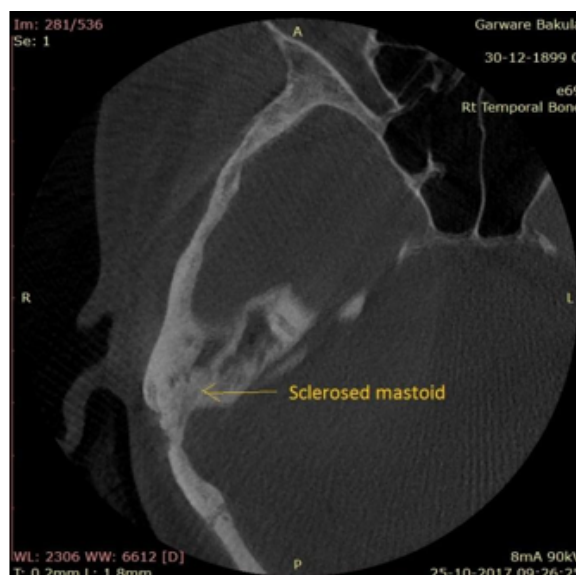

Fig. 4: CBCT image showing sclerosed Mastoid

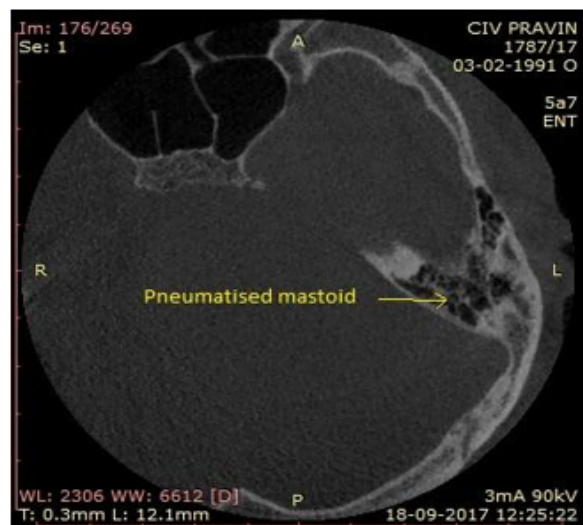


Fig. 3: CBCT image showing pneumatized Mastoid

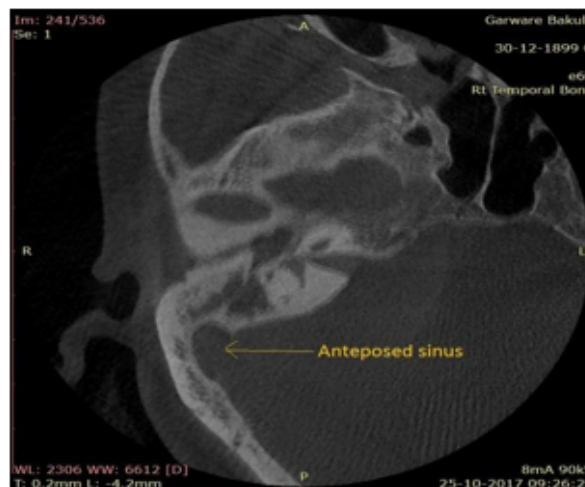

Fig. 5: CBCT image showing anteposed sigmoid sinus

Table 1: Showing active and inactive diseases in the study.

Activity	Frequency	Percentage (%)
Active	60	63.2
Inactive	35	36.8
Total	95	100.0

management plan if any.

The study included 95 patients, out of which 60 (63.16%) were males and 35 (36.84%) were females. 47.4% of the patients had disease pathology in left ear and 52.6% had disease pathology in right ear. Majority of the patients were between 20 to 50 years of age corresponding to 86.3%.

Active disease with a history of otorrhea in the past 12 weeks was seen in 63.2% of the patients whereas 36.8% had inactive disease in the current study [Table 1]. Tympanoplasty in 32.6% patients and Cortical Mastoidectomy with Tympanoplasty in 67.4% of the patients.

Subsequent to imaging, the management plan was changed in only 4 patients with a total of 28.4% undergoing Tympanoplasty and rest 71.6% undergoing Tympanoplasty with Cortical Mastoidectomy.

The change in management plan post imaging was however non-significant as determined by Mc Nemar's test with a P value of 0.125 (more than >0.05 at 95% confidence interval) [Fig 1]. CBCT was performed in all the patients and its findings were corroborated with the intra-operative findings in order to detect sensitivity and specificity of CBCT. Intra-operative findings are gold standard and serve as the baseline to which imaging findings can be corroborated with.

Pneumatisation of Mastoid, anatomical variations like high jugular bulb, low-lying dura and ossicular erosions were evaluated with CBCT [Figures 2, 3, 4 and 5]. Mastoid was sclerosed in 71.6% of the patients, pneumatised in 28.4%, high jugular bulb was seen in 15.8%, low lying dura was seen in 14.7% and ossicular erosion was not seen in any of the patients as determined by CBCT in our study. All the findings were corroborated by intra-operative findings except for one patient with ossicular erosion. This gave a 100% sensitivity, specificity, positive predictive value and negative predictive value for CBCT to detect pneumatisation of the Mastoid, high jugular bulb and low-lying dura. The sensitivity to detect ossicular erosion was 98.9% [Table 2]. These values suggest that all the findings of CBCT correlate with what is detected intra-operatively especially with regards to pneumatisation of Mastoid, high jugular bulb, low lying dura and ossicular erosions. Mastoidectomy is done along with Tympanoplasty as a management plan to treat COM (Mucosal) with a history of otorrhea in the past 12 weeks considering it to be an active disease corroborating it with the imaging findings. In our centre, generally, patients with active disease and sclerosed and

poorly pneumatised Mastoids on X-Rays are taken up for Cortical Mastoidectomy and Tympanoplasty.¹⁷ Hence, on the basis of imaging findings, it was further decided that some of the patients would require Cortical Mastoidectomy and only Tympanoplasty would not suffice.¹⁸ When the jugular bulb reached or exceeded the level of the floor of Internal Acoustic Meatus, it was defined as a High Jugular bulb.¹⁹ In our study, we identified a high jugular bulb in 15 out of 95 cases accounting to 15.8%. This finding helped us avoid any inadvertent injury to jugular bulb. Zhaohui L et al.²⁰ noted low lying dura in 21.8% of the patients when they studied anatomic variations of Temporal Bone. Dura is said to be low-lying if it is below the level of the attic roof.²¹ Low lying dura can hamper disease clearance and can lead to inadvertent injury to dura. In our study low lying dura was seen in 14 out of 95 cases accounting to 14.7%.

Güldner C et al. evaluated anatomy in normal and pathologic middle ears using CBCT.¹⁰ They concluded in their study that CBCT imaging in diseases of the lateral skull base or Temporal Bone is very much similar to conventional CT. They also inferred that all the structures were clearly visible almost every time in both the groups. However, they noted that looking at the ossicular chain, smaller structures, like the head of the Stapes or the crura of the Stapes, showed significant limitations in clear identification. In our study, we identified ossicular erosion intraoperatively in only one case accounting to 1.1%, which was missed on CBCT. Dahmani-Causse et al. compared techniques of Computed Tomography scans on evaluating Temporal Bone anatomic variations and pathologies and showed that CBCT provides effective morphological assessment of Temporal Bone due to better spatial resolution than Multislice Helical CT with a significantly lesser radiation dose.²²

According to Raffery et al, CBCT radiation levels are just around 10% those of Multislice CT and 6-10% according to Barker et al.^{23,24} CBCT thus carries a lower risk of radiation exposure and further side effects of it to the individual getting exposed to it. Radiation exposures by CBCT are only 2-3 times higher than conventional X-Ray Temporal Bone with significantly more information provided.²⁵

Considering a high sensitivity and specificity in identification of certain important parameters of Chronic Otitis Media and also to detect any variations in anatomical structures, CBCT can be considered as an ideal imaging technique in such patients.

4. Advantages

1. This study uses CBCT which has only minimal difference in the radiation exposure as compared to X-Ray mastoids but a vast difference as compared to HRCT Temporal Bone. The Computed Tomographic Dose Index (CTDI) of a CT scan of the middle ear is around 170 mGy and it is 15 - 30 mGy for CBCT.³

2. CBCT can be used in gathering information about the disease process and the effects of it as compared to X-Ray skull which gives only limited information in the form of extent of pneumatization and approximate levels of the sinus and Dural plates.
3. CBCT machines are compact and it can be installed in an OPD setting and even operating room assistants can be trained in operating them.

5. Limitations

1. The study did not compare the findings of CBCT with other conventional diagnostic imaging such as CT, MSCT scans to arrive at comparative figures.
2. Small inner ear structures and other pathologies such as labyrinthine fistula, Dural erosions, etc. were not evaluated and may have their own limitations in accurately visualizing them.

6. Conclusion

This study showed a high utility of CBCT in deriving useful information from the patients of Chronic Otitis Media and its benefit of less radiation exposure as compared to conventional CT. CBCT has a high specificity, sensitivity, positive predictive value and negative predictive value in detecting pneumatization of Mastoid, high Jugular bulb, low lying dura and ossicular erosions when corroborated with intra-operative findings. Though thorough clinical examination remains the gold standard in making a management plan of patients with Chronic Otitis Media (Mucosal), CBCT with its available details and minimal radiation helped to minimise intraoperative inadvertent injuries which might have resulted due to normal anatomic variations like low lying dura, forward lying sinus, contracted mastoid cavity etc. Its use can also be extended for follow up of cochlear implantees as it has low sensitivity to artefacts and it may replace the conventional X-Ray skull in future.²⁶

7. Source of Funding

None.

8. Conflict of Interest

None.

References

1. George G, Swan R, Saumil N, Merchant G, Iain RC. Chronic Otitis Media. *Head & Neck Surgery*. 2008;p. 3396–445.
2. Dworschak UW, Diogo I, Strack L, Mandapathil M, Teymoortash A, Werner JA. Indications of cone beam CT in head and neck imaging in children. *Acta Otorhinolaryngol Ital*. 2017;37(4):270–5.
3. Hodez C, Taillandier CG, Bensimon I. Cone-beam imaging: applications in ENT. *Eur Ann Otorhinolaryngol Head Neck Dis*. 2011;128(2):65–78.
4. Haidar H, Sheikh R, Larem A, Elsaadi A, Abdulkarim H, Ashkanani S. Ossicular chain erosion in chronic suppurative otitis media. *Otolaryngol*. 2015;5(4):203.
5. Leighton SE, Robson AK, Anslow P, Milford CA. The role of CT imaging in the management of chronic suppurative otitis media. *Clin Otolaryngol*. 1993;18(1):23–32.
6. Walshe P, Walsh M, Brennan R, Walsh P. The role of computerized tomography in the preoperative assessment of chronic suppurative otitis media. *Clinical Otolaryngol*. 2002;27(2):95–102.
7. Yates PD, Flood LM, Banerjee A, Clifford K. CT scanning of middle ear cholesteatoma: what does the surgeon want to know? *Br J Radiol*. 2002;75(898):847–52.
8. Payal G, Pranjali K, Gul M, Mittal MK, Rai AK. Computed tomography in chronic suppurative otitis media: value in surgical planning. *Indian J Otolaryngol Head & Neck Surg*. 2012;64(3):225–34.
9. Kozerska M, Skrzat J, Spulber A, Walocha J, Wroński S, Tarasiuk J. Micro-CT study of the dehiscences of the tympanic segment of the facial canal. *Surg Radiol Anat*. 2017;39(4):375–82.
10. Güldner C, Diogo I, Dräger BE, Mandapathil S, Teymoortash M, Negm A. Visualization of anatomy in normal and pathologic middle ears by cone beam CT. *Eur Arch Oto-Rhino-Laryngol*. 2017;274(2):737–79.
11. Zou J, Lähelmä J, Arnisalo A, Pyykkö I. Clinically relevant human Temporal Bone measurements using novel high-resolution cone-beam CT. *J Otol*. 2017;12(1):9–17.
12. Peltonen LI, Aarnisalo AA, Kortensniemi MK, Suomalainen A, Jero J, Robinson S. Limited cone-beam computed tomography imaging of the middle ear: a comparison with multislice helical computed tomography. *Acta Radiol*. 2007;48(2):207–19.
13. Scarfe WC, Farman AG. What is cone-beam CT and how does it work? *Dent Clin North Am*. 2008;52(4):707–37.
14. Lata S, Mohanty SK, Vinay S, Das AC, Das S, Choudhury P. Is Cone Beam Computed Tomography (CBCT) a Potential Imaging Tool in ENT Practice? A Cross-Sectional Survey Among ENT Surgeons in the State of Odisha. *Indian J Otolaryngol and Head & Neck Surg*. 2017;70:1–7.
15. Peltonen LI, Aarnisalo AA, Käser Y, Kortensniemi MK, Robinson S, Suomalainen A. Cone-beam computed tomography: a new method for imaging of the Temporal Bone. *Acta Radiol*. 2009;50(5):543–51.
16. Kashiba K, Komori M, Yanagihara N, Hinohira Y, Sakagami M. Lateral orifice of Prussak's space assessed with a high-resolution cone beam 3-dimensional computed tomography. *Otology Neurotol*. 2011;32(1):71–7.
17. Bhat KV, Naseeruddin K, Nagalotimath US, Kumar PR, Hegde JS. Cortical Mastoidectomy in quiescent, tubotympanic, chronic otitis media: is it routinely necessary? *J Laryngol Otol*. 2009;123(4):383–90.
18. Sayit AT, Gunbey HP, Fethallah B, Gunbey E, Karabulut E. Radiological and audiometric evaluation of high jugular bulb and dehiscence high jugular bulb. *J Laryngol Otol*. 2016;130(11):1059–63.
19. Vachata P, Petrovicky P, Sames M. An anatomical and radiological study of the high jugular bulb on high-resolution CT scans and alcohol-fixed skulls of adults. *J Clin Neurosci*. 2010;17(4):473–81.
20. Zhaohui L, Zhenchang W, Junfang X, Kun Z, Hong Z. HRCT study of anatomic variations of Temporal Bone. *Chin Arc Otolaryngol Head Neck Surg*. 2006;2(12):97–101.
21. Alam-Eldeen MH, Rashad UM. Radiological requirements for surgical planning in cochlear implant candidates. *Indian J Radiol Imag*. 2017;27(3):274–81.
22. Causse MD, Marx M, Deguine O, Fraysse B, Lepage B, Escude B. Morphologic examination of the Temporal Bone by cone beam computed tomography: comparison with multislice helical computed tomography. *Eur Ann Otorhinolaryngol Head Neck Dis*. 2011;128(5):230–5.
23. Rafferty MA, Siewerdsen JH, Chan Y, Daly MJ, Moseley DJ, Jaffray DA. Intraoperative cone-beam CT for guidance of Temporal Bone surgery. *Otolaryngol Head and Neck Surg*. 2006;134(5):801–9.
24. Barker E, Trimble K, Chan H, Ramsden J, Nithiananthan S, James A, et al. Intraoperative use of cone-beam computed tomography in a

- cadaveric ossified cochlea model. *Otolaryngol Head and Neck Surg.* 2009;140(5):697–702.
25. Wall BF, Hart D. Report on a recent review of doses to patients from medical X-ray examinations in the UK by NRPB. National Radiological Protection Board. *Brit J Radiol.* 1997;70(833):437–46.
26. Ruivo J, Mermuys K, Bacher K, Kuhweide R. Cone Beam Computed Tomography, a low dose imaging technique in the post-operative assessment of cochlear implantation. *Otol Neurotol.* 2009;30(3):299–303.

Renu Rajguru, Professor  <https://orcid.org/0000-0003-3814-6577>

Dilip Raghavan, Professor

Cite this article: Nitin S, Rajguru R, Raghavan D. A study to evaluate the change in management plan of chronic otitis media (mucosal) after cone beam computed tomography. *IP J Otorhinolaryngol Allied Sci* 2022;5(3):66-71.

Author biography

Shantha Nitin, Senior Resident