

Content available at: <https://www.ipinnovative.com/open-access-journals>

IP Journal of Otorhinolaryngology and Allied Science

Journal homepage: <https://www.joas.co.in/>

Case Report

Droopy swelling behind the ear lobe mimicking cyst or cancer

Sphoorthi Basavannaiah^{1,*}

¹Dept. of ENT, Subbaiah Institute of Medical & Dental Sciences, Shivamogga, Karnataka, India



ARTICLE INFO

Article history:

Received 02-06-2021

Accepted 09-07-2021

Available online 04-08-2021

Keywords:

Epidermoid cyst

Dermoid cyst

Head and Neck region

Ear

Pinna

ABSTRACT

Epidermoid and dermoid cysts occur anywhere from the skin covering the body. Clinicians and Surgeons often have an indicative impasse as there are plenty of cystic lesions in the Head and Neck region. Clinically, these cysts are asymptomatic that appear as uniform, round, doughy masses with a tiny surface opening. If by chance cyst gets infected the lining ruptures that spills out cheesy keratin debris into surrounding soft tissue giving rise to local tenderness and swelling.

This is an Open Access (OA) journal, and articles are distributed under the terms of the [Creative Commons Attribution-NonCommercial-ShareAlike 4.0 License](https://creativecommons.org/licenses/by-nc-sa/4.0/), which allows others to remix, tweak, and build upon the work non-commercially, as long as appropriate credit is given and the new creations are licensed under the identical terms.

For reprints contact: reprint@ipinnovative.com

1. Introduction

Head and neck constitutes about 7% of all cases that includes epidermoid and dermoid cysts. There is often a diagnostic dilemma as there are more common cystic lesions in this region. Both epidermoid and dermoid cysts are subcutaneous cyst lined by a thin layer of ectodermal squamous epithelium having a diverse intricacy.¹⁻⁶ Epidermoid cysts have cheesy material composed of sebum and epithelial debris made from squamous epithelium but dermoid cysts contain hair, sebaceous glands, sweat glands and squamous epithelium. Acquired types of both arise from trapped pouches or near normal folds of ectoderm following traumatic imbedding of squamous epithelium or blockade of duct of sebaceous glands. Congenital cysts develop as surface ectoderm fails to separate from the neural tube embryologically.²⁻⁹ Here, is one such patient who presented with droopy swelling behind the left ear lobe which looked benign but with a possibility of being malignant.

2. Case Report

Adult male comes to ENT outpatient department with swelling behind the left ear since more than 3 months. The swelling was gradual in onset and progressive since then to have attained the present size as described below. Initially was a size of a seed to have attained the present size of a cherry. There is no pain, discharge from the swelling. There are no other ear/nose or throat complaints to offer. Patient had normal built, nourishment and oriented. Both general physical and systemic examination were within normal limits. On local examination of the left ear as shown in Figures 1 and 2 there is a 2X2 cm swelling noted behind the left ear lobule arising from the inferior margin of the postauricular groove/ area and also involving the skin of the ear lobule. The swelling had smooth surface, regular margins, firm in consistency and non-tender on palpation. The swelling was mobile in nature with stem attached at the region of the inferior border of the postauricular groove. The skin over the swelling was non adherent to the swelling and was pinchable. There was no significant change in the surrounding skin around the swelling. There was no colour changes, vessels or any pulsations, any discharge seen over the swelling and also around the swelling. There was no

* Corresponding author.

E-mail address: sphoorthi86@rediffmail.com (S. Basavannaiah).

punctum seen over the swelling. The swelling was seen raising the lobule of the left ear and was hanging down due to its weight. The external auditory canal, tympanic membrane of the left ear were within normal limits. Right ear examination, Nose and Throat were within normal limits.

Excision of the swelling was planned under Local anaesthesia. Under aseptic precautions, the swelling was excised and sent for histopathological examination. Patient on first follow up, wound healthy after suture removal as shown in Figure 3.

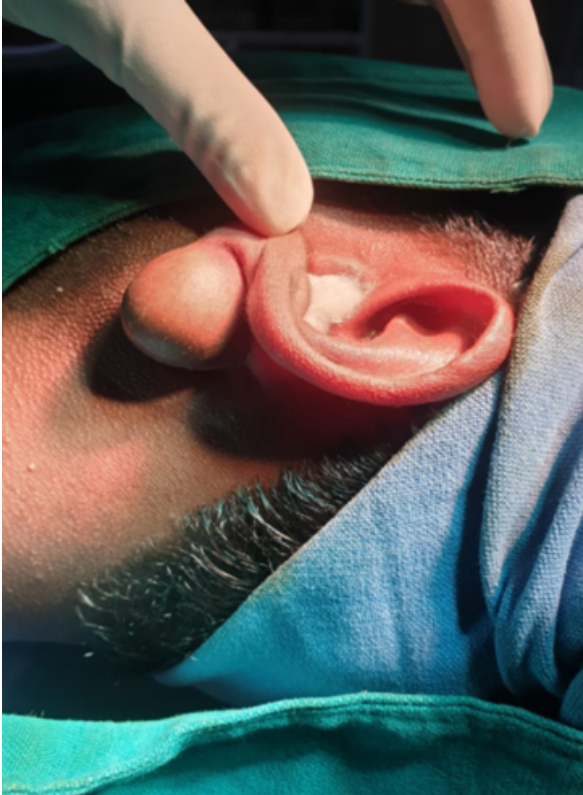

Fig. 1:

Preoperative picture of the swelling behind the left ear lobe, Postoperative picture after removal of the swelling from the left ear lobe. Histopathological report suggests cyst wall lined by stratified squamous epithelium with hypergranulosis. Lumen is filled with keratin debris. No atypical changes seen. Hence, suggestive of Epidermoid cyst as shown below in Figures 4, 5, 6, 7 and 8

Figures 4, 5, 6, 7 and 8: shows the cyst wall lined by stratified squamous epithelium with hypergranulosis and keratin debris filled in the lumen.

3. Discussion

Epidermoid and dermoid cysts can be of congenital or acquired type. Most dermoid cysts are congenital while

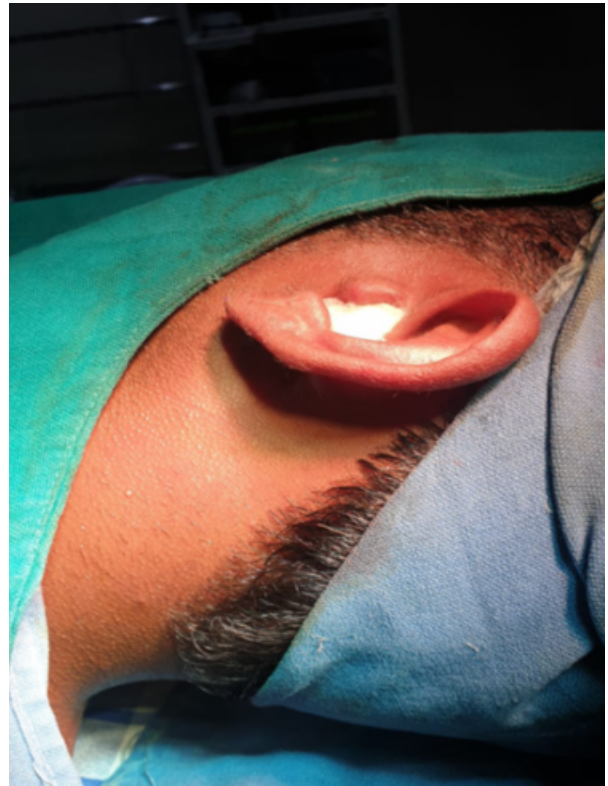

Fig. 2:

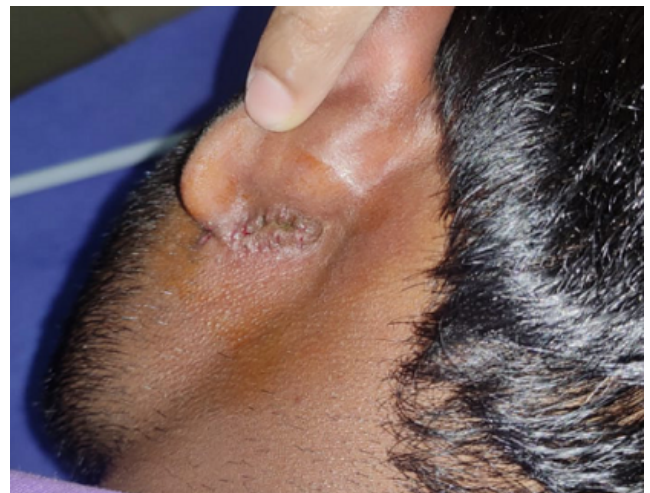

Fig. 3: 10 days after suture removal on first follow up.

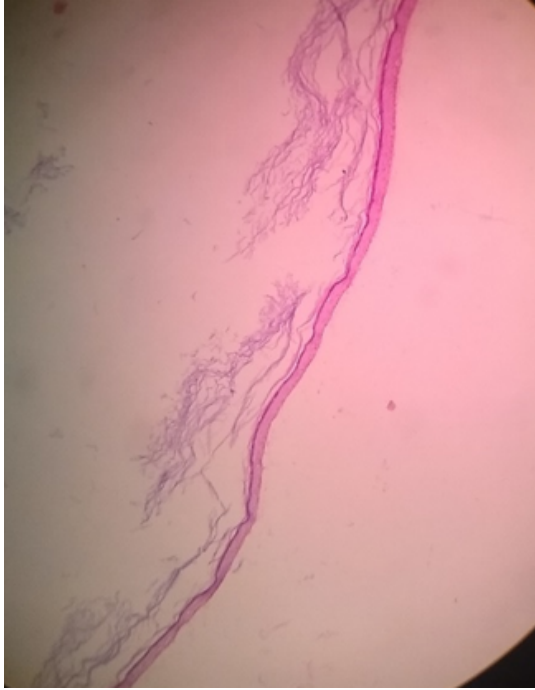


Fig. 4:

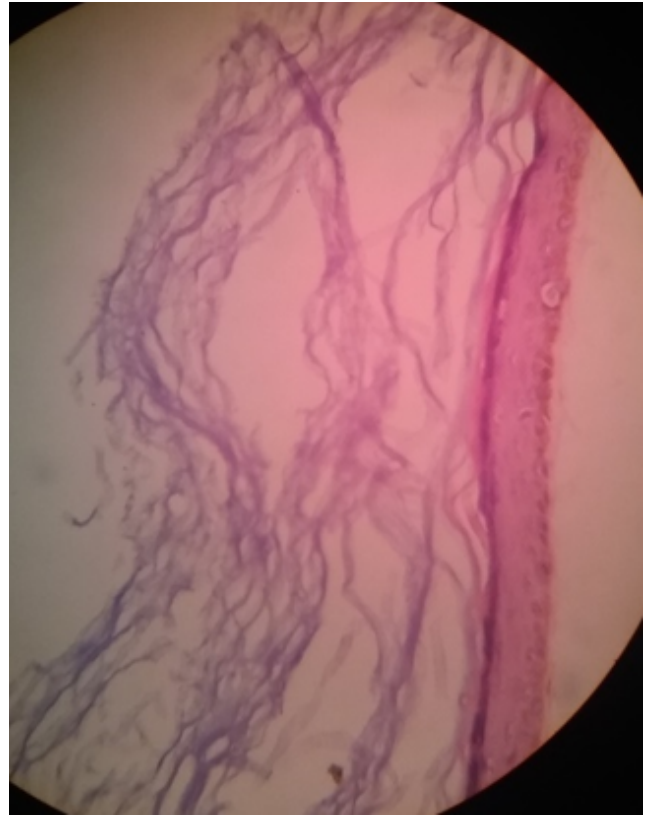


Fig. 6:

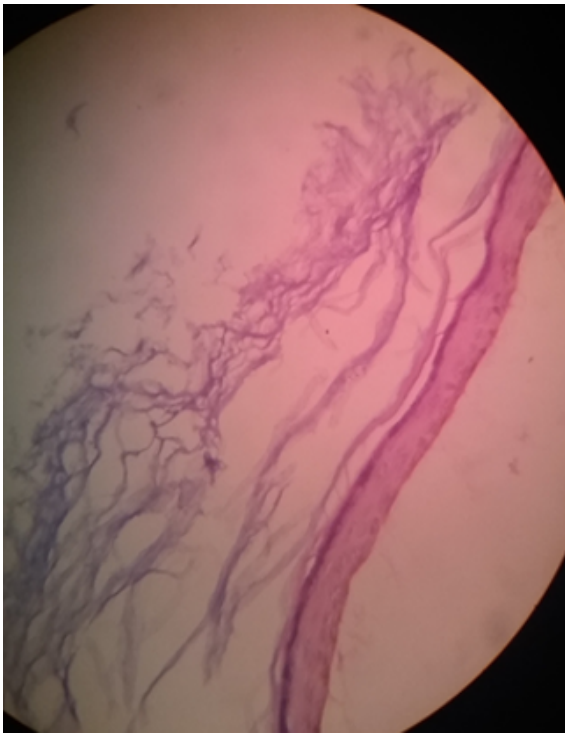


Fig. 5:

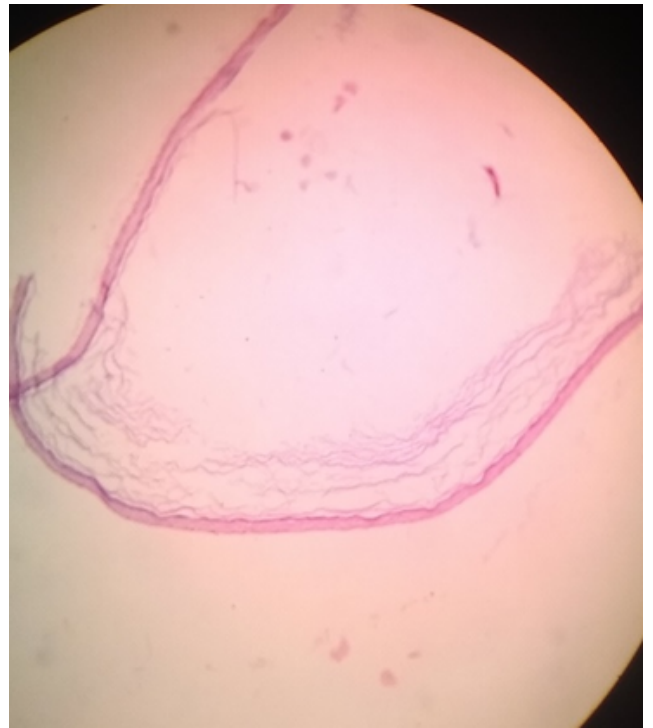


Fig. 7:

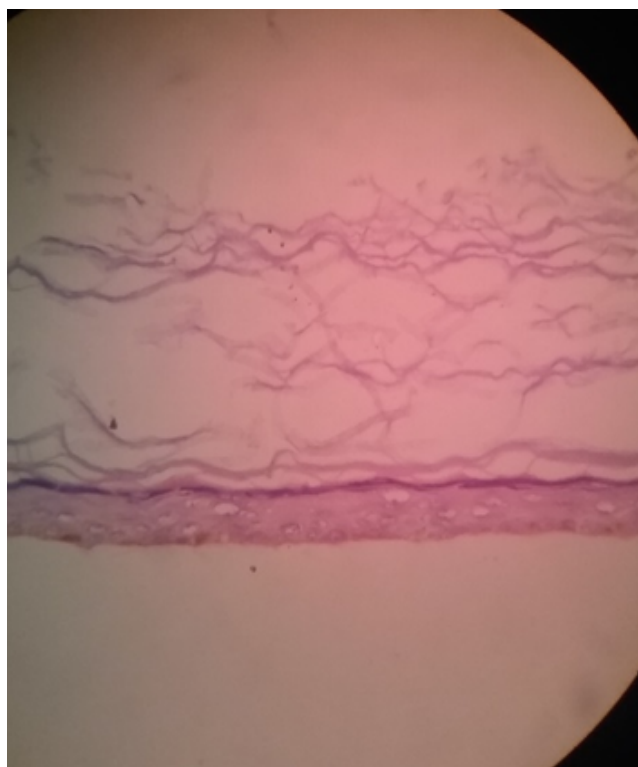


Fig. 8:

epidermoid cysts of the skin are acquired type. Congenital type of both are due to failure of surface ectoderm to separate from underlying neural tube and result from entrapment of ectodermal tissue between midline fusion of 1st and 2nd branchial arches in the head and neck regions.⁷ Entrapment of ectodermal tissue along embryologic sites of dermal fusion leads to epidermoid and dermoid cyst in the head and neck regions. Acquired type occur due to infection around pilosebaceous follicle or deep embedding of epidermis due to penetrating or blunt injury as in ear piercing etc.¹⁻⁵

Histologically, the above mentioned two cutaneous cysts differ in their internal structures especially in the lining of the wall. Both share common features- keratinized, eosinophilic and stratified squamous epithelium with laminated keratin debris within the thin wall. However, sebaceous and sweat glands, hair follicles are present only in dermoid but not in epidermoid cysts.³⁻⁶ Epidermoid cysts are covered by stratified squamous epithelium without adnexal structures but dermoid cyst contains keratin, sebaceous glands, hair follicles and adnexal structures within the wall of stratified squamous epithelium. There are only few reported cases of iatrogenic dermoid cyst as most of them are usually congenital, especially intracranial ones.¹⁰ Although, pathogenesis of epidermoid cyst is varied. Congenital type may result from embedding of epidermal rest during embryonal period. As most of the

times entrapment of ectodermal tissue occur along the embryologic sites of dermal fusion in the head and neck region. Traumatic type, usually occurs after ear piercing following trauma or iatrogenic implementation of epidermal tissues and proliferation into the surrounding tissue.⁸ Idiopathic type may derive from blockage of hair cortex follicles and occlusion of a sebaceous gland after repeated infection of the pilosebaceous unit as in our case.¹⁻⁵ The origin of the auricle is formed by 6 Hillocks of His that is the first and second branchial arch. These hillocks fuse each other and grow to form an auricle. During this developmental period, epidermoid and dermoid cyst can be developed. But in this study as this adult patient had a short history of 3 months, likely reason is Idiopathic Epidermoid cyst and is not of any embryological origin. This study showed that most cutaneous cysts of the auricle are epidermoid cyst likewise in this case report even.^{6,7}

Excision is the only treatment option for both Epidermoid and Dermoid cysts. The surgical technique involves many factors and is based on the anatomical characteristic of the location, if any requirement of grafting after complete excision to cover the defect, to maintain cosmesis of the area involved after removal and to prevent recurrence of the swelling after excision. In our case, after excision there was presence of extra skin which was removed and in order to maintaining cosmesis skin was closed.

4. Conclusion

Idiopathic Epidermoid cysts are benign cystic lesions lined by ectodermal squamous epithelium especially the ones in and around the ear. They are uncommon in the Head and Neck areas which constitute < 10% of all cases of Epidermoid and Dermoid cysts. Hence, the most cutaneous cysts developing around the ear are said to be Epidermoid cysts which are more likely to be non-malignant, thereby ruling out the probable chances of being cancerous.

5. Source of Funding

None.

6. Conflict of Interest

None.

References

1. Cho Y, Lee DH. Clinical characteristics of Idiopathic Epidermoid and Dermoid cysts of the ear. *J Audiol Otol.* 2017;21(2):77–80. doi:10.7874/jao.2017.21.2.77.
2. Kim GW, Park JH, Kwon OJ, Kim DH, Kim CW. Clinical characteristics of epidermoid cysts of the external auditory canal. *J Audiol Otol.* 2016;20(1):36–40. doi:10.7874/jao.2016.20.1.36.
3. Sabhalok SS, Shetty LS, Sarve PH, Setiya SV, Bharadwaj SR. Epidermoid and dermoid cysts of the head and neck region. *Plast Aesthet Res.* 2016;3(11):347–50. doi:10.20517/2347-9264.2016.09.

4. Jung KH, Choi HJ, Nam DH. Characteristics of dermoid cyst of the auricle. *Arch Craniofac Surg*. 2014;15:22–29.
5. Park JS, Ko DK. A histopathologic study of epidermoid cysts in Korea: comparison between ruptured and unruptured epidermal cyst. *Int J Clin Exp Pathol*. 2013;6(2):242–50.
6. Dutta M, Saha J, Biswas G. Epidermoid cysts in Head and Neck, our experiences with Review of literature. *Indian J Otolaryngol Head Neck Surg*. 2013;65(1):14–21. doi:10.1007/s12070-011-0363-y.
7. Kim HK, Kim SM, Lee SH, Racadio JM, Shin MJ. Subcutaneous epidermal inclusion cysts: ultrasound (US) and MR imaging findings. *Skeletal Radiol*. 2011;40(11):1415–9. doi:10.1007/s00256-010-1072-4.
8. Aziz AM. Epidermoid cyst of the external auditory canal in children: diagnosis and management. *J Craniofac Surg*. 2011;22(4):1398–400. doi:10.1097/SCS.0b013e31821cc2fe.
9. Görür K, Talas DU, Ozcan C. An unusual presentation of neck dermoid cyst. *Eur Arch Otorhinolaryngol*. 2005;262(4):353–5. doi:10.1007/s00405-004-0813-1.
10. Dabholkar JP, Patole AD, Sheth AS, Saaj R. Congenital cystic lesions in head and neck. *Indian J Otolaryngol Head Neck Surg*. 2003;55(2):128–30. doi:10.1007/BF02974621.

Author biography

Sphoorthi Basavannaiah, Associate Professor

Cite this article: Basavannaiah S. Droopy swelling behind the ear lobe mimicking cyst or cancer. *IP J Otorhinolaryngol Allied Sci* 2021;4(2):70-74.