

Ingestion of corrosive caustic soda crystals mimicking candy-coated rock sugar: Prank or perplexity!!!

Sphoorthi Basavannaiah

Assistant Professor, Dept. of ENT, Subbaiah Institute of Medical Sciences, Shimoga, Karnataka, India

Abstract

Sodium hydroxide decomposes proteins at conventional ambient temperatures causing austere chemical burns as it is has both caustic base with alkali property. It is useful in various commercial factory outlets but is also very harmful when it comes in contact causing saponification and liquefaction of various body tissues to molecular level. Here is an interesting case wherein the patient presented to the Emergency department with unintended consumption of caustic soda crystals, as a “slice of hoax”.

Keywords: Sodium hydroxide, Caustic soda, liquefaction, saponification, Corrosive.

Case Report

20 year old adult male reported to the Emergency department with accidental ingestion of caustic soda crystals (as in Fig. 1) (as a part of “prank” or “perplexed” it to be ‘rock sugar’ (as in Fig. 2).



Fig. 1: Solid Caustic crystals



Fig. 2: Hard Rock sugar crystals

He gives history of respiratory distress, dysphagia, burning sensation in the oral cavity and pain in the throat. He also complains of vomiting with no blood contents in it. He is a vegetable cutter at our hospital mess and a chronic alcoholic.

He was well oriented and with vitals stable and maintained saturation. Systemic examination was within normal limits.

*Corresponding Author: Sphoorthi Basavannaiah, Dept. of ENT, Subbaiah Institute of Medical Sciences, Shimoga, Karnataka, India
Email: sphoorthi86@rediffmail.com

Local examination: Oral cavity/Throat- excoriation of skin over the lips, swollen upper and lower lips, superficial burns involving the left side of buccal mucosa, left retromolar trigone, hard and soft palate. Tip and lateral aspect of the tongue were swollen and erythematous.

On Video-laryngoscopic examination (as in Fig. 3): Laryngeal edema and congestion (“Ballooned up appearance”) of epiglottis with excessive pooling of secretions. B/L Vocal cords and subglottis view were obscured.

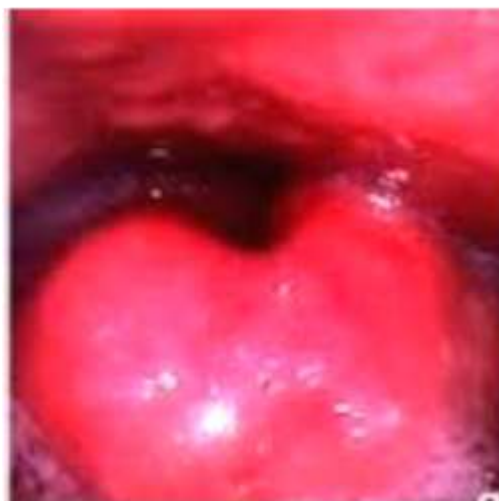

Fig. 3: Ballooned up appearance of epiglottis with laryngeal edema and vocal cords not visualised.

Patient kept under observation for 24 hours in Intensive care unit with continuous monitoring of vitals (raised Pulse rate/ low Blood pressure/ drop in saturation), if any evidence of respiratory distress, hematemesis. Intravenous fluids as maintenance @ 100ml/hr, Injection Hydrocort 100mg iv STAT and later 6 hourly, Injection Compose 5mg im STAT, Injection Taximax 1.5gm iv 12 hourly, Injection Pan 40 mg

iv (4 vials) in 100ml Normal saline infusion over ½ hour STAT and later Injection Pan 40mg iv 6 hourly, Injection Dynapar- AQ 75mg im STAT, Injection Emeset 4 mg iv SOS, Syrup. Sucralfate 100 ml thrice, Mucomix nebulisation, Head end elevation, High risk /Tracheostomy consent (if patient de-saturates or goes into inspiratory stridor).

Day 1: Oral cavity /oropharynx: Edema and congestion subsided (as in Fig. 4). Burns reduced over tip of tongue, buccal mucosa, hard and soft palate (as in Fig. 5). On VDL examination: Edema over the epiglottis subsided (as in Fig. 6) with congested arytenoids (as in Figure 6) with rest of the larynx barely visualised.

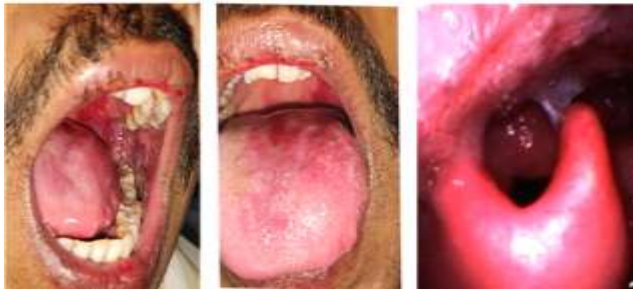

Fig. 4,6,7: Showing signs of inflammation in the oral cavity and larynx.

Patient was better in terms of symptoms. Only sips of cold water, iv fluids continued as maintenance, Injection Hydrocort 100mg iv 6 hourly, Injection Taximax 1.5 gm iv 12 hourly, Injection Pan 40mg iv 12 hourly, Syrup. Sucralfate 100ml thrice.

Day 2: Throat/ Larynx examination: Erythema over tongue, buccal mucosa, palate comes to normal (as in Fig. 7). Edema over epiglottis drastically reduced with slough seen (as in Fig. 8). Congestion over arytenoids reduced. Vocal cords normal and mobile (as in Fig. 9) while subglottis well visualised (as in Fig. 10).

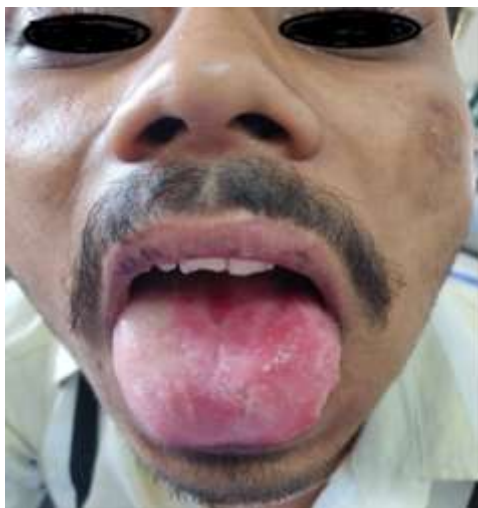

Fig. 7: Erythema seen over tongue.

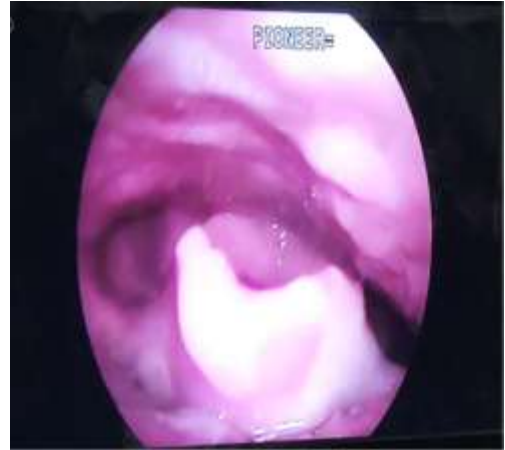


Fig. 8: Edema reduced over epiglottis with slough seen.

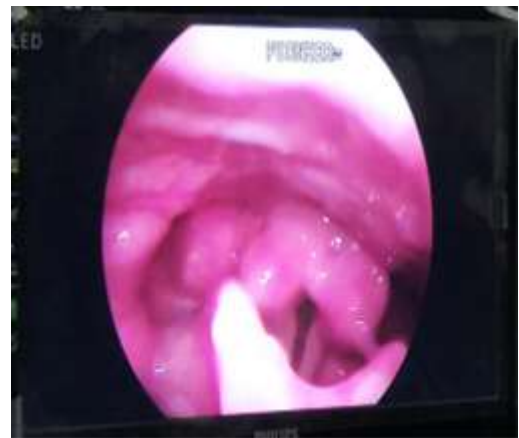

Fig. 9: Vocal cords normal and mobile.

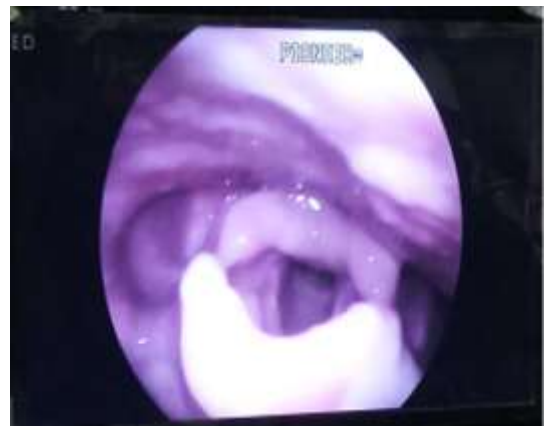


Fig. 10: Subglottis normal in appearance.

Patient was symptomatically better. The patient was kept on liquid diet while rest of the treatment was followed as same which was given on Day 1.

Discharge advice on Day 2: Start Oral bland diet, T. Gramocof-CV 200 mg twice for 5 days, T. Pan -D thrice for 5 days, T. Defcort 6mg thrice for 2 days, twice for 2 days, once for 2 days, T. Emeset 4mg 1 SOS, Syrup. Sucralfate 1 tsp thrice, Oraways gel for local application.

Patient asked to follow up after 5 days or review back immediately if any complaints of dysphagia (to rule out oesophageal stricture or hematemesis). After 5 days, Patient was better (as in Figure 11 and 12). After 15 days, when patient was followed up he was doing well and having a normal routine.

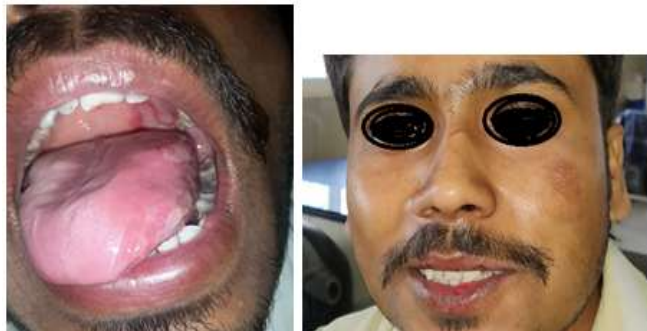

Fig. 11,12: Patient recovered well with near normal appearance of oral cavity.

Discussion

Sodium hydroxide (NaOH) is addressed with variety of names on routine households and manufacture industries as lye, caustic soda which is a white solid, inorganic compound consisting of sodium cations and hydroxide anions. With its strong alkaline property, it is preferred in paper and pulp industry, extraction from bauxite ore and cleansing applications in breweries, bakeries and food processing industries.^{1,4,7} It is taken as a powerful means for pH adjustment, neutralizing water streams and is also contributory in reducing corrosion in water treatment process. It is used in the manufacture of silicates, phosphates, bleach, detergents and soaps and refining of vegetable and mineral oils.^{5,8,11}

Due to its highly caustic base and alkali property, it can decompose proteins at normal temperatures causing gross chemical burns. It is one of the simplest hydroxides which is frequently utilized with neutral water and hydrochloric acid to demonstrate pH scale to chemistry students. It is commercially available as monohydrate in various industries and used in manufacture of pulp & paper, soaps, detergents, textile business, purification of drinking water and as caustic cleaner.^{6,9,10}

Ingesting caustic constituents' results in tissue and organ damage causing wide range of complications including loss of function. Usually alkalis are vicious in nature because of their lytic action on body tissues. Distributions of chemical burns vary based on type of alkali ingestion. Solid alkalis produce profound burns as they adhere to oral mucosa. On the other hand, liquid alkalis enter oesophagus as they can be easily swallowed.^{2,6,8,11} They produce liquefactive necrosis which progressively encroach deeper layers of tissue producing extensive injuries. Caustic elements cause destruction of tissue by saponification and liquefactive reactions and the intensity of destruction depends on variety of factors such as type, concentration, time of contact and amount of the substance ingested.^{4,7,9,12} As in this case, patient took few crystals of

caustic soda as part of prank or perplexity and held it in his mouth. Before he could realise of its burn, patient spit it out immediately. Only a very minimal amount of the crystals were swallowed unknowingly. This resulted in superficial burns in the oral cavity with scarring, laryngeal edema without oesophageal injury falling under mild degree of superficial burns.^{1,3,5,10}

Conclusion

Accessibility to lye can be avoided with regards to improving its storage but not using soft drink and water bottles for preserving and also their crystals should not be stored at eatery places where there can be chances of accidental ingestion. Corrosive ingestion is liable especially in people with no formal education and poor socio-economic status. Non-compliance to good practices of storage and clearance of caustic soda during prepping process can increase its ingestion and contact in children. Such group of people should be targeted for education about creating safe working and storing environments. Educating people will increase cognizance of perils associated with corrosive substance ingestion. This is necessary to guard against haphazard handling of such destructive agents. Enforcement of chemical hazards legislation is important to control the custom of lye which is required to ensure that containers should be tightly sealed making it inaccessible to adults and also children to prevent easy access to corrosive agents.

Source of Funding

None.

Conflict of Interest

None.

References

1. Gupta SK, Rana AS, Gupta D, Jain G, Puneet KP. Unusual Presentation of Caustic Ingestion and its Surgical Treatment: A Case Report. *J Maxillofac Oral Surg* 2011;10(1):74-6.
2. Lupa M, Magne J, Guarisco JL, Amedee R. Update on the diagnosis and treatment of caustic ingestion. *Ochsner J* 2009;9(2):54-9.
3. Meredith JW, Kon ND, Thompson JN. Management of injuries from liquid lye ingestion. *J Trauma* 2008;28(8):1173-8.
4. Lionte C, Sorodoc L, Petris OR, Sorodoc V. Unusual presentation and complication of caustic ingestion. *J Gastrointest Liver Dis* 2007;16(1):109-12.
5. Salzman M, O'Malley RN. Updates on the evaluation and management of caustic exposures. *Emerg Med Clin North Am* 2007;25(2):459-76.
6. Mattos GM, Lopes DD, Mamede RC, Ricz H, Mello-Filho FV, Neto JB. Effects of time of contact and concentration of caustic agent on generation of injuries. *Laryngoscope* 2006;116(3):456-60.
7. Varkey P, Tan NC, Chen HC. Corrosive injury of oral cavity—a rare presentation. *J Plast Reconstr Aesthet Surg* 2006;59(10):1110-3.
8. Arévalo SC, Eliashar R, Wohlgeleitner J, Elidan J, Gross M. Ingestion of caustic substances: a 15-year experience. *Laryngoscope* 2006;116(8):1422-6.

9. Ryan F, Witherow H, Mirza J, Ayliffe P. The oral implications of caustic soda ingestion in children. *Oral Surg Oral Med Oral Pathol Oral Radiol Endod* 2006;101(1):29-34.
10. K, Gumaste VV. Corrosive ingestion in adults. *J Clin Gastroenterol* 2003;37(2):119-24.
11. Mamede RM, Mello FV. Ingestion of caustic substances and its complications. *Sao Paulo Med J/Rev Paul Med* 2001;119(1):10-5.
12. Schaffer SB, Hebert AF. Caustic ingestion. *J La State Med Soc* 2000;152(12):590-6.

<p>How to cite this article: Basavannaiah S, Ingestion of corrosive caustic soda crystals mimicking candy- coated rock sugar: Prank or perplexity!!!. <i>J Otorhinolaryngol Allied Sci</i> 2019;2(3):77-80.</p>
--