

Content available at: <https://www.ipinnovative.com/open-access-journals>

IP Journal of Otorhinolaryngology and Allied Science

Journal homepage: <https://www.joas.co.in/>

## Case Report

# A case report on use of ivermectin as nasal drop in a case of nasal myiasis

Vartika Paliwal<sup>1</sup>, Sudhakar Vaidya<sup>1\*</sup>

<sup>1</sup>Dept. of ENT, R.D. Gardi Medical College & C.R. Gardi Hospital, Ujjain, Madhya Pradesh, India



## ARTICLE INFO

### Article history:

Received 15-03-2024

Accepted 11-04-2024

Available online 01-05-2024

### Keywords:

Nasal myiasis

Topical parasitocides

Endoscopy

Irrigation

Suction and clearance

## ABSTRACT

We describe a case of nasal myiasis due to in a 52-year-old Hindu priest with a previously known case of right sided hemiparesis with diabetes mellitus. Initial attempts to remove the fly larvae using manual extraction with a toothed forceps and normal saline irrigation were unsuccessful. On subsequent nasal irrigation after instillation of ivermectin tabs crushed in normal saline as nasal drops, the patient self-expulsed some larvae, and rest larvae were cleared on subsequent nasal suction and clearance. He also received a course of oral ivermectin. Here, we propose that the antiparasitic oral tablet ivermectin can be used in a nasal drop formulation for the aid of nasal myiasis.

This is an Open Access (OA) journal, and articles are distributed under the terms of the [Creative Commons Attribution-NonCommercial-ShareAlike 4.0 License](#), which allows others to remix, tweak, and build upon the work non-commercially, as long as appropriate credit is given and the new creations are licensed under the identical terms.

For reprints contact: [reprint@ipinnovative.com](mailto:reprint@ipinnovative.com)

## 1. Background

Myiasis presents commonly in tropical regions, characterized by tissue infestation by fly larvae, known as maggots. Flies typically deposit their eggs in open wounds or near inflamed skin, often caused by moisture. These eggs hatch within 8 to 24 hours, with the larvae penetrating damaged skin, creating deep lesions prone to bacterial infection. Without treatment, these chronic wounds progress, leading to septicemia and potentially death.

Conventional treatment involves manual removal of larvae, wound cleaning, surgical removal of dead tissue, and dressing application. Larvae removal is challenging and painful, often necessitating the use of topical parasitocides like ivermectin. Ivermectin, applied topically, selectively binds to chloride ion channels, increasing cell permeability and causing nerve or muscle cell hyperpolarization, ultimately leading to parasite death.

## 2. Case Report

A 52 year old male came in ENT OPD with the complain of nasal bleeding and recurrent sneezing since 1 day. He was a known case of right sided hemiparesis, with history of covid infection complicated with rhinocerebral mucormycosis- operated in 2022. He had history of diabetes mellitus during covid infection for which he was on medication in 2022, then stopped medication as his sugar levels came to normal. On General Examination he was average built, well oriented, Cooperative B Pmmhg Pulse74/minutes normovolumic with regular rhythm, afebrile, all point of examination like piccwere absentdetected. Local Examination of nose was done. There was side. Crusting was found on mucous membrane, and septum was found deviated towards right with mid septal tear in right nasal cavity. Live Maggots were found in septal tear, ethmoid and maxillary sinus opening. On Post Rhinoscopy examination there was no Post Nasal Trickling investigations which are necessary in the preop period. The patient was then planned for debridement and suction clearance of maggots.

\* Corresponding author.

E-mail address: [vartikapaliwal10@gmail.com](mailto:vartikapaliwal10@gmail.com) (S. Vaidya).

## 2.1. Investigations

1. ENT profile- CBC, Urine R/M, Blood sugar, RFT, LFT was done.  
Blood sugar: Random – 220mg/dl and Fasting – 120mg/dl TLC count- 14000/microliters rest everything was within normal limits.
2. CT PNS was suggestive of nasal mucosa atrophy with multiple maggots present extending to ethmoid sinus, maxillary sinus, frontal sinus and base of skull.
3. Direct nasal endoscopy shown multiple live maggots moving out of sinuses and in nasal cavity.

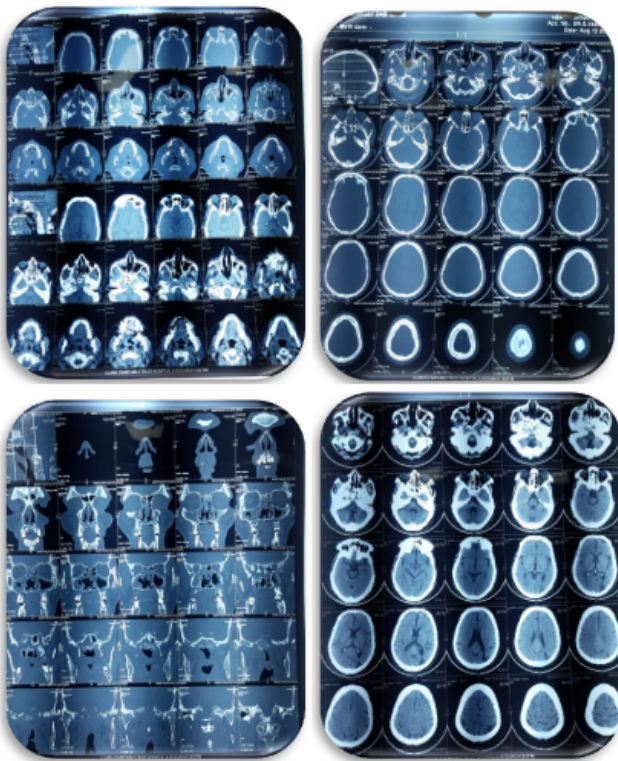


Figure 1:

## 2.2. Management

Patient was started with injectable antibiotics, ceftriaxone 1gm I/V BD and the patient was also given oral antiparasitic medication i.e. 12mg tab ivermectin daily for 3 days. Normal Saline drops mixed with crushed 2 tabs of ivermectin 12mg were also instilled in patient with frequency of 2 drops QID. Multiple sitting of Nasal endoscopy suction and clearance was done under LA with sedation and under local anesthesia. Multiple washes were given and Dead Maggots were removed from ethmoid sinus, maxillary sinus, sphenoid sinus and base of skull and septum followed by continued nasal washing with ivermectin saline solution.

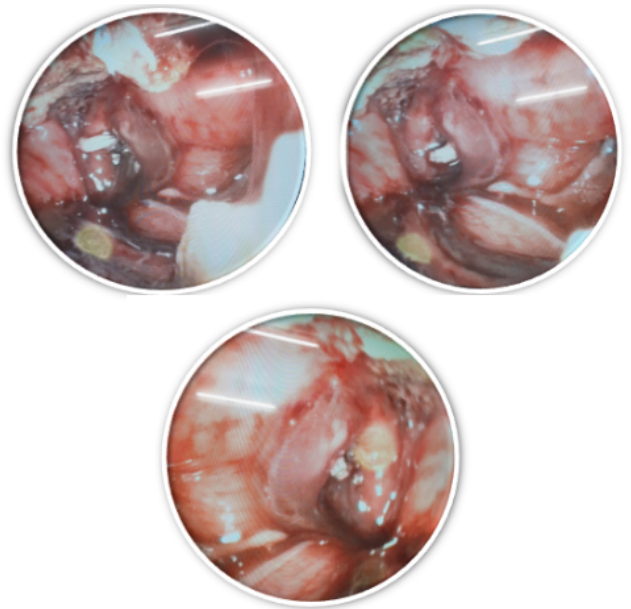


Figure 2:

## 3. Discussion

Myiasis is a condition in humans caused by the infestation of fly larvae belonging to the Diptera order.<sup>1,2</sup> Fly larvae from various families including Muscoidea (such as *Musca domestica*, the common house fly), Oestridae (for instance, *Oestrus ovis*, the Sheep Nasal fly), Calliphoridae (like *Cochliomyia hominivorax*, the New World Screwworm fly), and Sarcophagidae (such as *Wohlfahrtia magnifica*, the Spotted flesh fly) are commonly associated with myiasis.<sup>3</sup> These larvae can be categorized as obligatory, facultative, or accidental parasites. In obligatory myiasis, maggots develop in and feed on non-necrotic tissue of living hosts, while facultative myiasis involves maggots feeding on necrotic tissues or decaying materials but not necessarily requiring a living host. Accidental myiasis occurs when larvae are inadvertently ingested or deposited in tissues, becoming accidental parasites.

Myiasis can also be classified based on the affected area. Nasal myiasis, unlike most forms, can lead to potentially fatal outcomes, often involving destruction of nasal soft tissue and bone. Complications such as pneumocephalus, secondary meningitis, and bacterial sepsis have been documented.<sup>4–8</sup> Risk factors identified in an Indian study include atrophic rhinitis, leprosy, poor nutritional status, and low socioeconomic status.<sup>4</sup> Similar to leprosy, mucocutaneous leishmaniasis ulcerations may predispose individuals to nasal myiasis, especially in those with low socioeconomic status and living in rural areas.

Although rare, cases of nasal myiasis have been reported in resource-rich countries, including among previously healthy travellers.<sup>9–11</sup> Additionally, locally

acquired cases have been observed in immunocompromised individuals,<sup>12–14</sup> and nosocomial nasal myiasis outbreaks have been documented in intensive care units in intubated and semi-conscious patients in USA,<sup>15–18</sup> Korea,<sup>19</sup> and Taiwan.<sup>20</sup>

Successful treatment involves complete removal of larvae to prevent secondary infections.<sup>3</sup> While extreme surgical interventions are avoided, topical agents like turpentine, mineral oil and chloroform and manual extraction remain common treatment modalities.<sup>3,7,21</sup> Endoscopic removal has emerged as the preferred treatment,<sup>12,22,23</sup> although multiple procedures may be necessary due to the high number of larvae sometimes present.<sup>24</sup>

Ivermectin, a semi-synthetic derivative of avermectin, has gained attention for its efficacy against various parasites, including those causing myiasis. It acts by disrupting neurotransmission through ligand-gated chloride channels in invertebrates, leading to paralysis and death.<sup>25</sup> Ivermectin's low affinity for mammalian central nervous system and inability to penetrate the blood-brain barrier make it safe for use. Recent research suggests additional immunomodulatory effects, further expanding its potential applications.<sup>26,27</sup> Successful use of oral ivermectin alongside manual extraction has been reported in treating nasal and rhino-orbital myiasis cases.<sup>7,9,28–30</sup> Dosages typically range from 2 mg to 0.2 mg/kg, with repeated courses possibly necessary.<sup>9</sup> Ivermectin is readily available in many resource-poor countries, often in liquid formulations.

#### 4. Conclusion

With this, the conclusion drawn from the case study was that the most effective tool found in the complete clearance of maggots was the solution made by combining crushed ivermectin tablet and saline. The vigorous routinely done nasal irrigation with this solution benefited the patient to a larger extent and resulted in complete clearance in approximately three to four settings. Thus the antiparasitic oral tablet IVERMECTIN can be used in a nasal drop formulation for the aid of nasal myiasis. It is important to note that the liquid formulation of ivermectin, which was used in our case, has twice the bioavailability of oral tablet.

#### 5. Source of Funding

None.

#### 6. Conflict of Interest

None.

#### References

1. Tay SY, Ramasamy BR, Watson DA, Montoya M. Treatment of nasal myiasis with ivermectin irrigation. *BMJ Case Rep.* 2018;p. bcr2017224142. doi:10.1136/bcr-2017-224142.
2. Mumcuoglu K. Other Ectoparasites: Leeches, Myiasis and Sand Fleas. *Manson's Trop Dis.* 2014;p. 843–7.
3. Francesconi F, Lupi O. Myiasis. *Clin Microbiol Rev.* 2012;25(1):79–105.
4. Sharma H, Dayal D, Agrawal SP. Nasal myiasis: review of 10 years experience. *J Laryngol Otol.* 1989;103(5):489–91.
5. Uriarte FJ, Ell SR. Doctor, there are maggots in my nose. *J R Soc Med.* 1997;90(11):634–5.
6. Kuruvilla G, Albert RR, Job A, Ranjith VT, Selvakumar P. Pneumocephalus: a rare complication of nasal myiasis. *Am J Otolaryngol.* 2006;27(2):133–5.
7. Thomas S, Nair P, Hegde K. Nasal myiasis with orbital and palatal complications. *BMJ Case Rep.* 2010;p. 4–7. doi:10.1136/bcr.08.2010.3219.
8. Mircheraghi SF, Mircheraghi SF, Riabi H, Parsapour A. Nasal nosocomial myiasis infection caused by chrysomya bezziana (diptera: calliphoridae) following the septicemia: a case report. *Iran J Parasitol.* 2016;11(2):284–9.
9. Smillie I, Gubbi PK, Cocks HC. Nasal and ophthalmomyiasis: case report. *J Laryngol Otol.* 2010;124(8):934–5.
10. Einer H, Ellegård E. Nasal myiasis by Oestrus ovis second stage larva in an immunocompetent man: case report and literature review. *J Laryngol Otol.* 2011;125(7):745–6.
11. Delhaes L, Bourel B, Pinat F, Cailliez JC, Gosset D, Camus D, et al. Human nasal myiasis due to Oestrus ovis. *Parasite.* 2001;8(4):289–96.
12. Badia L, Lund VJ. Vile bodies: an endoscopic approach to nasal myiasis. *J Laryngol Otol.* 1994;108(12):1083–12.
13. Villwock JA, Harris TM. Head and neck myiasis, cutaneous malignancy, and infection: a case series and review of the literature. *J Emerg Med.* 2014;47(2):e37–41.
14. Jan TA, Redjal N, Walcott BP. Intranasal myiasis: a rare complication of transnasal skull base surgery. *J Clin Neurosci.* 2013;20(8):1178–80.
15. Beckendorf R, Klotz SA, Hinkle N, Bartholomew W. Nasal myiasis in an intensive care unit linked to hospital-wide mouse infestation. *Arch Intern Med.* 2002;162(6):638–40.
16. Tai R, Marsh MA, Rao R, Kurniali P, DiNino E, DiNino E, et al. Nasal myiasis caused by cochliomyia hominivorax in the united states : A case report. *Am J Infect Dis.* 2011;7(4):107–9.
17. White ZL, Chu MW, Hood RJ. Nasal Myiasis: A Case Report. *Ear Nose Throat J.* 2015;94(7):24–5.
18. Ahadzadeh EN, Ketchum HR, Wheeler R. Human cutaneous myiasis by the australian sheep blowfly, lucilia cuprina (diptera: calliphoridae), in oklahoma. *J Forensic Sci.* 2015;60(4):1099–100.
19. Kim JS, Seo PW, Kim JW, Go J, Jang S, Lee H, et al. A nasal myiasis in a 76-year-old female in Korea. *Korean J Parasitol.* 2009;47(4):405–7.
20. Lee YT, Chen TL, Lin YC, Fung CP, Cho WL. Nosocomial nasal myiasis in an intubated patient. *J Chin Med Assoc.* 2011;74(8):369–71.
21. Gupta SC. Permanent closure of the nostrils in recurrent nasal myiasis. *J Laryngol Otol.* 1978;92(7):627–8.
22. Baptista M. Nasal Myiasis. *N Engl J Med Overseas Ed.* 2015;372(12):e17. doi:10.1056/NEJMicm1403473.
23. Ranga R, Yadav SPS, Goyal A, Agrawal A. Endoscopic Management of Nasal Myiasis: A 10 Years Experience. *Clin Rhinol Int J.* 2013;6(1):58–60. doi:10.5005/jp-journals-10013-1152.
24. Hoyer P, Williams RR, Lopez M, Cabada MM. Human Nasal Myiasis Caused by Oestrus ovis in the Highlands of Cusco, Peru: Report of a Case and Review of the Literature. *Case Rep Infect Dis.* 2016;p. 2456735. doi:10.1155/2016/2456735.
25. Schnizler K, Saeger B, Pfeffer C, Gerbaulet A, Ebbinghaus-Kintscher U, Methfessel C, et al. A novel chloride channel in Drosophila melanogaster is inhibited by protons. *J Biol Chem.* 2005;280(16):16254–62.
26. Crump A. Ivermectin: enigmatic multifaceted 'wonder' drug continues to surprise and exceed expectations. *J Antibiot.* 2017;70:495–505. doi:10.1038/ja.2017.11.

27. Corrêa AP, Beneti IM, Ribeiro ED, Pereira CCS, Souza F, Garcia-Júnior IR, et al. Myiasis in elderly involving oral and nasal cavities- diagnosis and treatment. *J Craniofac Surg*. 2015;26(3):989–90.
28. Macdonald PJ, Chan C, Dickson J, Jean-Louis F, Heath A. Ophthalmomyiasis and nasal myiasis in New Zealand: a case series. *N Z Med J*. 1999;112(1100):445–7.
29. Babamahmoudi F, Rafinejhad J, Enayati A. Nasal myiasis due to *Lucilia sericata* (Meigen, 1826) from Iran: a case report. *Trop Biomed*. 2012;29(1):175–9.
30. Costa DC, Pierre-Filho PT, Medina FM. Use of oral ivermectin in a patient with destructive rhino-orbital myiasis. *Eye*. 2005;19:1018–20. doi:10.1038/sj.eye.6701713.

### **Author biography**

**Vartika Paliwal**, Junior Resident

**Sudhakar Vaidya**, HOD

**Cite this article:** Paliwal V, Vaidya S. A case report on use of ivermectin as nasal drop in a case of nasal myiasis. *IP J Otorhinolaryngol Allied Sci* 2024;7(1):12-15.