

Content available at: <https://www.ipinnovative.com/open-access-journals>

IP Journal of Otorhinolaryngology and Allied Science

Journal homepage: <https://www.joas.co.in/>

## Case Series

# Outcomes of endoscopic guided adenoidectomy versus conventional adenoidectomy

Rukma Bhandary<sup>1</sup>, Rinshin T<sup>1,\*</sup>

<sup>1</sup>Dept. of ENT, A.J. Institute of Medical Sciences, Mangaluru, Karnataka, India



## ARTICLE INFO

### Article history:

Received 17-05-2023

Accepted 06-06-2023

Available online 11-08-2023

### Keywords:

Conventional adenoidectomy

Endoscopic adenoidectomy

Microdebrider

## ABSTRACT

**Introduction:** Adenoidectomy is one of the most common surgical procedures performed on children. Conventional curettage adenoidectomy is a low-cost procedure that is still widely practised, particularly in developing nations.

**Aim:** To compare conventional curettage adenoidectomy and endoscopic-assisted powered adenoidectomy using a microdebrider.

**Materials and Methods:** Consecutive cases for Conventional Adenoidectomy (Group I) and Endoscopic Assisted Adenoidectomy (Group II) were taken from cases undergoing adenoidectomy, with each group consisting of 20 patients. The operating time and postoperative pain score were measured and compared between the two groups. Patients were evaluated at the first and sixth weeks to measure subjective improvement of symptoms, DNE was performed to evaluate remaining adenoid tissue and scarring of adjacent structures.

**Results:** The total operating time in groups I and II was 13 minutes (range: 10-15 minutes) and 21 minutes (range: 15-25 minutes), respectively. In 12 cases, remnant adenoid tissue ranged from 25 to 50%. Ten of them received conventional adenoidectomy. Group I experienced significantly higher postoperative pain than group II.

**Conclusion:** Endoscopic adenoidectomy is a safe and effective alternative to conventional curettage. It favours consistent restoration of nasopharyngeal patency, improved haemostasis, and reduced postoperative pain.

This is an Open Access (OA) journal, and articles are distributed under the terms of the [Creative Commons Attribution-NonCommercial-ShareAlike 4.0 License](https://creativecommons.org/licenses/by-nc-sa/4.0/), which allows others to remix, tweak, and build upon the work non-commercially, as long as appropriate credit is given and the new creations are licensed under the identical terms.

For reprints contact: [reprint@ipinnovative.com](mailto:reprint@ipinnovative.com)

## 1. Introduction

Wilhelm Meyer, in 1885, first described conventional adenoidectomy and since then it has been one of the most frequently performed surgical procedures in the pediatric age group.<sup>1,2</sup> Adenoid hypertrophy producing nasopharyngeal blockage with subsequent sleep disordered breathing, otitis media with effusion, recurrent otitis media, and recurrent rhinosinusitis are all indications for adenoidectomy.<sup>1,3-5</sup>

There are two technical surgical procedures for removing adenoids:

- Conventional curettage adenoidectomy
- Endoscopic assisted adenoidectomy

Traditional curettage adenoidectomy is a low-cost procedure that is still widely practised, particularly in developing nations. It is, however, a blind process that frequently leads to complications and inadequate removal. This study aims to compare the outcome of endoscopic assisted adenoidectomy and conventional curettage adenoidectomy and assess which is a better surgical modality

\* Corresponding author.

E-mail address: [rinshin9@gmail.com](mailto:rinshin9@gmail.com) (Rinshin T).

## 2. Materials and Methods

Endoscopic aided adenoidectomy and conventional adenoidectomy cases were posted among those undergoing adenoidectomy. Each of the surgeries were performed under general anaesthesia with orotracheal intubation and the patient in Rose's posture. Draffin's bipod in Magauraun's plate supports Boyle-Davies' mouth gag with tongue blade put in the oral cavity. Adenoids were palpated with the index finger in patients undergoing conventional adenoidectomy. A St. Clair Thomson adenoid curette was then introduced into the nasopharynx and adenoid tissue is curetted out. The nasopharynx is palpated once again, and any remaining remnants are curetted out. The pack was then put in the nasopharynx double the clotting time. The endoscope was used in conjunction with a microdebrider in oscillating mode with saline irrigation in the endoscopic approach. Curettage of adenoid tissue was performed with 45-rad adenoidectomy blades oscillating at 2,400 rpm. A rigid endoscope with a diameter of 2.7 or 4 mm was used to monitor the procedure. To view the operating end of the microdebrider, an angled 45-70° scope was placed through the oral cavity. Total operating time, completeness of adenoid tissue removal, and collateral injury to surrounding tissues are all intraoperative parameters observed. All patients' postoperative recovery times were documented. The entire operative time was calculated as the time between initial insertion and the final removal of the mouth gag. At the sixth week of follow-up, nasal endoscopy was used to assess the completeness of adenoid removal. The total number of days required to return to regular activities (recovery time) as determined by asking the patient/guardian during the routine postoperative follow-up.

## 3. Results

Out of a total of 40 patients, 20 underwent endoscopic aided adenoidectomy (group II) and 20 underwent conventional adenoidectomy (group I). The patients' ages ranged from one year to fourteen years.

The total operating time in groups I and II was 13 minutes (range: 10-15 minutes) and 21 minutes (range: 15-25 minutes), respectively. The total operational time difference between the two groups was statistically significant. Twelve of the 40 individuals exhibited remaining adenoid tissue ranging from 25 to 50%.

Ten of them received conventional adenoidectomy. It came to light that it was statistically significant.

Postoperative pain was substantially higher in group I than in group II, most likely due to harm to nearby structures. There was no significant difference in recovery time between the two techniques in either group.

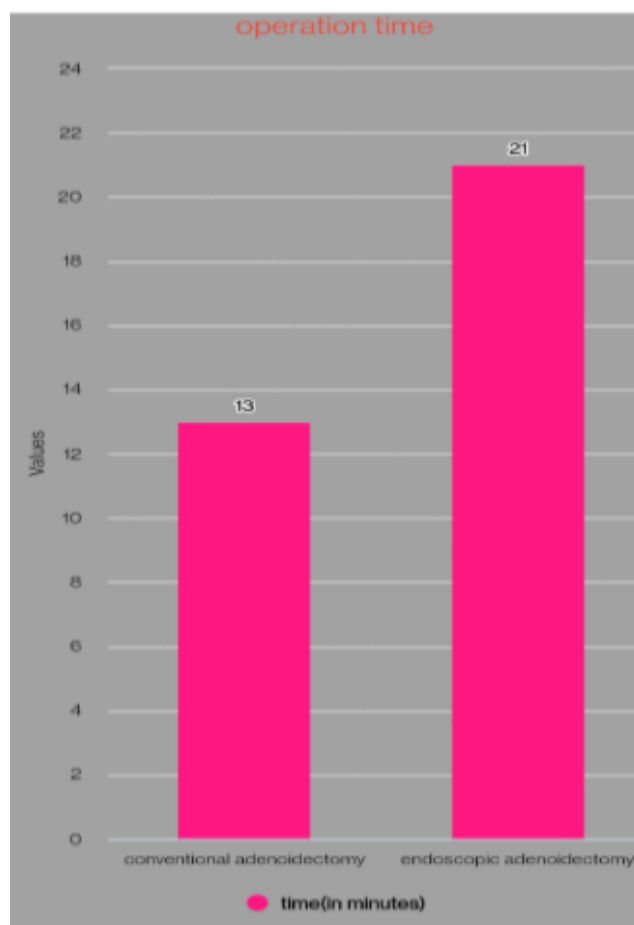


Fig. 1:

## 4. Discussion

Adenoidectomy is a frequent procedure in most hospitals. Conventional curettage adenoidectomy is a low-cost technique that does not necessitate the use of specialised or expensive equipment and can be conducted in hospitals without advanced operating room facilities. Although conventional curettage adenoidectomy is a quick and easy procedure, since it is a blind technique it has its own set of complication. Various studies have reported a high percentage of residual tissue following this technique<sup>6,7</sup> This study also found remnant tissue in the choana in children who had conventional adenoidectomy. In our study, 12 instances showed remnant adenoid tissue ranging from 25 to 50%.

Ten of them underwent conventional adenoidectomy. More than 50% of the remnant adenoid was found in two cases of conventional adenoidectomy.

In study by Songu M, et al.<sup>8</sup> found that the operative time of curettage adenoidectomy was around 7 minutes and with endoscopic guidance to be around double that time where as in our study total operative times in groups I and II

were 13min (range 10–15 min) and 21min (range 15–25 min), respectively. According to a study by Datta et al, post-operative pain was less in the endoscopic adenoidectomy group than in the conventional adenoidectomy group, although the difference was not statistically significant. However, we discovered a statistically significant difference between pain scores in our study. When compared to conventional adenoidectomy, patients who had endoscopic aided adenoidectomy experienced less pain. But there was no significant difference in recovery time following the two technique.

The newer method of endoscopic-assisted power adenoidectomy was found to be a safe and useful tool for adenoidectomy. The advantages of this technique include completeness of resection, accurate removal, less damage to adjacent structures, less postoperative pain, and faster recovery. Endoscopic-assisted power adenoidectomy has been found to be a safe and useful tool for adenoidectomy. This approach has several advantages, including complete removal, accurate removal, less injury to surrounding structures, reduced postoperative pain, and speedier recovery.

#### 5. Source of Funding

None.

#### 6. Conflict of Interest

None.

#### References

1. Ungkanont K, Damrongsak S. Effect of adenoidectomy in children with complex problems of rhinosinusitis and associated diseases. *Int J Pediatr Otorhinolaryngol.* 1969;90(3):447–51.
2. Al-Mazrou KA, Al-Qahtani, I Fayed A. Effectiveness of transnasal endoscopic powered adenoidectomy in patients with choanal adenoids. *Int J Pediatr Otorhinolaryngol.* 2009;73(12):1650–2.
3. Costantini F, Salamanca F, Amaina T, Zibordi F. Videoendoscopic adenoidectomy with microdebrider. *Acta Otorhinolaryngol Ital.* 2008;.
4. Mitchell RB. Adenoidectomy techniques for sleep disordered breathing. *Oper Tech Otolaryngol.* 2005;16(4):229–60.
5. Wang DY, Clement PA, Kaufman L, Derde MP. Chronic nasal obstruction in children. A fiberoptic study. *Rhinology.* 1995;33(1):4–6.
6. Cannon CR, Replogle WH, Schenk MP. Obstructive adenoid tissue: an indication for powered-shaver adenoidectomy. *Arch Otolaryngol Head Neck Surg.* 1999;121(6):789–91.
7. Havas T, Lowinger D. Obstructive adenoid tissue: an indication for powered-shaver adenoidectomy. *Arch Otolaryngol Head Neck Surg.* 2002;128(7):789–91.
8. Songu M, Altay C, Adibelli ZH, Adibelli H. Endoscopic assisted versus curettage adenoidectomy: a prospective, randomized, double-blind study with objective outcome measures. *Laryngoscope.* 2010;120(9):1895–904.

#### Author biography

**Rukma Bhandary**, Associate Professor

**Rinshin T**, PG Student

**Cite this article:** Bhandary R, Rinshin T. Outcomes of endoscopic guided adenoidectomy versus conventional adenoidectomy. *IP J Otorhinolaryngol Allied Sci* 2023;6(2):43-45.