



Original Research Article

Comparative Efficacy of intra-tympanic methylprednisolone injections in different concentrations on subjective cochlear tinnitus

Manish Gupta^{1,*}, Monica Gupta², Satish Kumar³

¹Dept. of ENT, Maharishi Markandeshwar Institute of Medical Sciences & Research, MMU, Ambala, Haryana, India

²Dept. of Internal Medicine, Government Medical College & Hospital, Chandigarh, India

³Dept. of ENT, Guru Gobind Singh Medical College and Hospital, Faridkot, Punjab, India



ARTICLE INFO

Article history:

Received 22-08-2020

Accepted 23-09-2020

Available online 24-10-2020

Keywords:

Tinnitus

IntraTympanic Perfusion Technique

Inner Ear

Treatment

ABSTRACT

Introduction: Subjective tinnitus is an awareness of a phantom sound which is audible solely to the individual. Intra-tympanic steroid injections especially dexamethasone 8mg/ml have been used with variable success in relieving it; however this desired concentration is unavailable in India. The aim of this study was to assess the comparative efficacy of intra-tympanic methylprednisolone injections in different concentrations in subjective cochlear tinnitus.

Materials and Methods: Ninety patients with complaint of abnormal ringing in uni/bilateral ear, with/without hearing loss were enrolled from our outpatient set-up. After written informed consent, the participants received a tinnitus loudness and frequency matching test. They were randomly assigned into three different subgroups (each with 30 patients) by a single-blind method. 0.5ml of 40mg/ml concentration methylprednisolone solution was injected intratympanically in study set one (Group A), 125mg/ml in second set (Group B) and 250mg/ml in the third set (Group C). The groups were compared in terms of subjective tinnitus intensity and loudness matching after the intervention.

Results: On subjective analysis of tinnitus intensity 1 patient of Group A and 2 each of groups B and C demonstrated improvement. On loudness matching test for tinnitus, no patient in Group A was cured, though 3 each in groups B and C were cured.

Conclusions : In the present study, no significant change was observed in the three treatment groups in subjective analysis of tinnitus intensity based on questionnaire. Similarly a non-significant response was obtained in loudness matching test for tinnitus. The intra-tympanic methylprednisolone injection gave suboptimal and inconsistent results at varying concentrations. Further prospective studies to evaluate the effect of intratympanic methylprednisolone on tinnitus are warranted in carefully selected group of patients.

© 2020 Published by Innovative Publication. This is an open access article under the CC BY-NC license (<https://creativecommons.org/licenses/by-nc/4.0/>)

1. Introduction

Tinnitus word is derived from 'tinnire', a Latin word meaning 'to ring'. It is defined as the perception of a sound in the ears or head in the absence of any external stimulant.¹ Tinnitus is generally thought of as an outcome of an increase in the spontaneous activity in the auditory neurons. Although maximum cases of tinnitus have a hearing loss, it can also present with a normal hearing capacity.¹ Subjective tinnitus (ST) is a conscious awareness

of a phantom sound, which only the patients are able to hear. It is generally by virtue of cochlear pathology, such as presbycusis, endolymphatic hydrops and noise induced hearing loss, although any component in whole auditory pathway may be involved.²

Tinnitus is one of the most frequent and troublesome otological disorder, causing variety of somatic and psychological complications, thus affecting the quality of life. Tinnitus appears to afflict 10-15% of the adult population.³ Patients with relentless tinnitus mostly suffer other hearing issues, for instance, hyperacusis, hearing loss or distorted perception of sounds, insomnia, concentration

* Corresponding author.

E-mail address: manishgupta1217@gmail.com (M. Gupta).

problems, irritability, depression and anxiety. Thus, tinnitus, may be labeled as a 'chronic stressor' for this section of the population.⁴ Standard modalities of management for tinnitus include hearing aid amplification, masking techniques, tinnitus retraining therapy, dietary modifications and pharmacological intervention in the form of anxiolytics, antidepressants or alternate complementary therapies. However, none of these modalities are really effective in the true sense.

Intra-tympanic (IT) treatment with variety of agents is getting more importance for this disorder over the last decade.⁵ The straight into ear application of medication through IT or trans-tympanic route, is a developing procedure in otology. Initially introduced in 1956 by Schuknecht to manage Meniere's disease, now inner ear injections are used in an array of diseases, namely sudden sensorineural hearing loss, autoimmune inner ear disease and tinnitus.⁶ IT injection has been used increasingly as a better modality than systemic administration as superior concentrations of the drug are attained in the target organ (inner ear) in a precise manner with minimum systemic side effects.⁷ In addition, when systemic steroids may be completely or partially ineffective in restoring hearing, direct IT injection of steroids have been employed with success.

Majority of the studies showing this beneficial effect in tinnitus have used dexamethasone at a concentration of 8mg/ml with underlying etiologies as sudden sensorineural hearing loss, Meniere's disease and idiopathic tinnitus.⁵ However, despite this success, the data should be viewed carefully as it is derived from uncontrolled retrospective research. In India, this concentration is unavailable; and the available 4mg/ml concentrations have yielded suboptimal results. Therefore, the IT injection of methylprednisolone (another potent steroid) was administered in various concentrations to arrive at the most effective dose.

2. Material and Methods

The study was carried out in outpatient department of Otorhinolaryngology, following approval from Institutional Ethical Committee. Informed consent was taken from all patients after explaining them all the risks involved and the benefits of the procedure undertaken. Ninety patients with complaint of abnormal ringing in uni/bilateral ear with/without hearing loss satisfying the inclusion and exclusion criteria (mentioned below) were selected. A detailed relevant history, general physical and otorhinolaryngological examination, microscopic examination, hearing tests and imaging studies (Computed Tomogram or Magnetic Resonance Imaging) of the selected patients was done. In every patient, after detailed history and its correlation with audiological tests, the clinical diagnosis of subjective cochlear tinnitus was conclusively proved. Tone decay was the topodiagnostic test used in our

study.

The cases were enrolled in the study based on all the following inclusion criteria; the patients having complaint of abnormal sounds in ear for at least one month, more than 18 years of age, having subjective tinnitus and no improvement with systemic drugs such as vasodilators, ginkgo biloba and vitamin B complex taken for at least four weeks in the past. The patients who quit the study or did not turned for follow up were not included in the study. Patients with tinnitus due to ear problem such as otitis media, eardrum perforation, eustachian tube dysfunction, temporomandibular joint dysfunction and retrocochlear disorders were excluded from the study. Similarly patients with otosclerosis, hypertension, diabetes mellitus, hypo/hyperthyroidism, objective tinnitus were also excluded.

All the patients underwent routine hematological tests- hemoglobin, total and differential leucocyte count, fasting plasma sugar, bleeding time, clotting time and a postero-anterior chest radiograph. The patients were asked to fill the questionnaire "Nature of tinnitus questionnaire" (Annexure I); with each question explained to them in their regional language. This questionnaire consisted of 14 questions that are useful in determining the nature of tinnitus. This gave fair idea about the side of the ear affected, whether tinnitus is episodic or continuous, the pitch, loudness and other factors influencing the loudness of tinnitus⁸. The participants who met the selection criteria and received a tinnitus loudness and frequency matching test were randomly assigned into three different subgroups by a single-blind method. Group A received 0.5 ml IT methylprednisolone solution injection at concentration of 40 mg/ml, Group B same volume @ 125 mg/ml and Group C @ 250 mg/ml.

2.1. IT injection technique

The patient was laid supine on an examining bed with head turned 45° away from the surgeon. Topical anesthesia was administered to the tympanic membrane with 4% lignocaine adrenaline pledget placed deep in the external auditory canal (EAC) adjacent to lateral surface of tympanic membrane or infiltration of 2% lignocaine with adrenaline in the EAC, in anxious patient. The assigned solution was pre-warmed to body temperature and injected under direct vision of operating microscope at the postero-inferior quadrant of the ear drum over the round window area, using a 27-gauge, 1.5 inches long needle over tuberculin syringe. The volume of instilled drug was usually 0.3 to 0.5 ml. The patient was kept in same position for about 30 minutes. The patients were instructed to avoid swallowing to avoid rapid passage of medication through the eustachian tube and to allow more time for the drug diffusion across the round window. Instead of swallowing, they were asked to spit their saliva into a kidney tray. A schedule of four such injections was maintained for every patient enrolled, two injections were administered during the first week

and then weekly for next two weeks. All the patients underwent pure tone audiometry and the tinnitus loudness-matching test immediately after the end of the sessions. An additional injection was given to those patients who demonstrated improvement in the tinnitus matching test. Dry ear precautions were recommended, till the injection site healed.

All the patients were followed with hearing test and questionnaire at 1 month and 6 month post therapy. If they did not return for follow up, they were contacted telephonically. The therapeutic efficacy of the drug was determined by relief in patient's symptoms and comparison of the results of the pure tone audiogram and loudness matching test for tinnitus before and after the treatment. The subjective analysis of tinnitus intensity was obtained by having patients rate their tinnitus from 0 to 10, with 10 being the loudest. Responses were graded as either 'improved', 'unchanged' or 'worse'. The tinnitus was defined 'cured' when the patients objectively felt no loudness in their ears 1 month post treatment, in the present trial. 'Improvement' when the loudness decreased by at least 5 dBSL by comparing tinnitus intensities obtained pre- and post-treatment or when persistent tinnitus became intermittent. Both these positive responses were considered to be effective. 'Control' of tinnitus declared when it did not increase in loudness in six month of follow-up. Following the data collection, comparison between the variables was made using analysis of variance; p value ≤ 0.05 was considered statistically significant.

3. Results

The study population consisted of 90 participants, of which 67 were males and 23 females; gender ratio 2.9/1. 49 patients were above 60 years of age, 32, 7 and 2 belonged to 40-60, 20-40 and less than 20 years respectively (Figure 1). On the basis of tinnitus loudness, 9 were classified as mild, 66 moderate and 15 had severe disabling level. The etiological factors responsible for ST in our study were presbycusis in 49 cases, Menière's disease in 13, noise induced hearing loss in 5 and ototoxicity in 4, while 19 had idiopathic tinnitus. 67 patients had associated sensorineural hearing loss. 43 had tinnitus for more than 2 years, 25 for more than one year while 22 had for less than a year, but more than a month. The tinnitus involved both ears in most of the cases (63%). In unilateral cases the tinnitus was more common in right ear. Tinnitus was continuous for majority (73%) and intermittent for rest of total patients. The majority of patients had high pitch tinnitus (67%). Also, the majority (73.33%) labeled their tinnitus to be moderately loud.

70% of the patients experienced momentary pain, vertigo and hearing loss/ heaviness in immediate post-injection period. However, all these symptoms got relieved spontaneously within 15-20 minutes. Though the pain was reported to be severe in 10 cases of Group C, it was milder

in the other two groups. There was no development of otitis media or persistent tympanic perforation in any of the study groups.

On subjective analysis of tinnitus intensity, based on the questionnaire, 1 patient of group A and 2 each of B and C experienced improvement. The majority of patients in all the groups had unchanged responses to the therapy. 1 patient in Group A reported worsening of tinnitus (Table 1).

On loudness matching test for tinnitus, 3 patients each in Group B and Group C were cured, however none in Group A. 3 patients in Group A, 6 and 7 in Group B and Group C respectively demonstrated improvement. Majority of patients, in all the three groups had control of tinnitus at 6 months, numerically they were 27, 21, 20 patients in Group A, Group B, Group C respectively (Table 2).

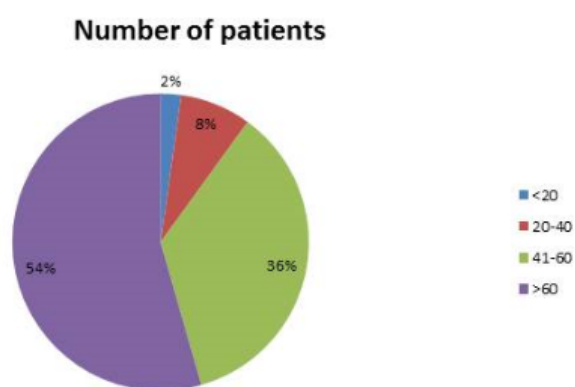


Fig. 1: Age-wise distribution of patients (in percentage).

4. Discussion

Corticosteroids play a key role in preventing and recovering from the cochlear damage due to their potent anti-inflammatory, immunosuppressive and mineralocorticoid effects.⁵ The inner ears of animal models and human temporal bones have presence of steroid and mineralocorticoid receptors.⁹ The mechanism of action of steroids in resolving tinnitus may include vasodilatation-induced increased microvascular circulation into the cochlea, suppression of irritability or hypersensitivity of the sensory cells in the inner ear, diminution of the autoimmunity-mediated inflammation and reduction of endolymphatic hydrops.¹⁰⁻¹² Repeated cochlear insults activate pro-inflammatory chemokines and cytokines and generate reactive oxygen species and nitric oxide. The cochlear tissue may undergo inflammatory damage in acute and chronic otitis media, hydrops, noise, ischemia, meningitis, ototoxic drugs and systemic inflammatory disease.¹³ This developing cochlear inflammation is receptive to glucocorticoid treatment.

IT perfusion of the inner ear banks upon permeation of the instilled drug through the round window (RW)

Table 1: Subjective analysis of tinnitus intensity based questionnaire

Treatment Groups	n=90	Response		
		Improved	Worse	No change
A (0.5ml; 40mg/ml)	n=30	1	1	28
B (0.5ml; 125mg/ml)	n=30	2	-	28
C (0.5ml; 250mg/ml)	n=30	2	-	28

Table 2: Response on Loudness matching test among the three groups

Treatment Groups	n=90	Response		
		Cured	Improved	Control
A (0.5ml; 40mg/ml)	n=30	-	3	27
B (0.5ml; 125mg/ml)	n=30	3	6	21
C (0.5ml; 250mg/ml)	n=30	3	7	20

membrane in the inner ear.¹⁴ The passage of medication through the round window membrane is determined by various factors. These include mechanical obstacle in middle ear, the round window membrane character, inflammation, thickness and specific characteristics of various medications like molecular weight, liposolubility, concentration and electrical charge.^{15,16} In an endeavor to enhance outcome, diverse methods have been designed to deliver medication through RW. Use of sustained release devices which transfer even trivial amount of drug in a highly focused manner to the RW membrane, has shown different concentration of medication in the perilymph, relying upon its position with respect to the RW membrane.¹⁷ In the study by Silverstein, placing a merocel wick through a myringotomy on to the round window worked well initially, but the response was not sustained and tympanic perforation persisted, thus its use was discontinued.¹¹ Middle ear exploration using laser assisted typanostomy and oto-endoscope to assess the round window niche before giving IT medication appears to be a promising technique.¹¹ Laser gives a bloodless opening through which the endoscope is passed and any mucosal adhesions or bands may be removed with otological needles. Some authors perform two myringotomies, for the displaced air from middle ear to escape while some place ventilation tubes for serial drug instillation.¹⁷

The optimum time for passage of drug through round window is 30 minutes, thus the patient is asked to maintain the head tilt position and avoid swallowing.¹⁸ After the drug gets absorbed in the scala tympani it gets diffused in the inner ear fluid all over by interscalar exchange.¹⁹ The concentration of medication, particularly steroids, achieved in inner ear fluid is higher via transtympanic instillation than with oral or intravenous administration.²⁰ Sakata et al assessed the efficacy of IT dexamethasone injection for treating cochlear tinnitus over two years and 1466 ears were treated. Infusion was given four times in a week over two weeks.²¹ To determine the level of tinnitus they used a 10-point subjective evaluation grading scale. The therapy was effective in 77% immediately after treatment and 68%

overall after 6 months. The competence rate was maximal for tinnitus following chronic otitis media, Meniere's disease and labyrinthine syphilis. Upper efficacy rates were also noted in patients with mild hearing loss, low pitch and low level tinnitus. It was less successful in tinnitus following streptomycin toxicity, post head injury and long-standing tinnitus.²¹ Silverstein et al used IT methylprednisolone (80mg/ml) in 46 patients with Meniere's, autoimmune inner ear disease, presbycusis and sudden sensorineural deafness. They found an overall improvement in tinnitus in 47% patients; out of which 60% were Meniere's.¹¹ Cesarani et al injected IT dexamethasone (4mg/ml) in 50 patients and observed that 34% had complete resolution of tinnitus and 40% had significant symptomatic relief.²² In another series involving 10 patients with tinnitus secondary to sensorineural hearing loss (non-responsive to oral steroids), IT perfusion of methylprednisolone (62.5mg/ml) was carried out and 60% demonstrated improvement, defined as a change of four points or more on a 10-point scale.²³ The IT steroid therapy has several advantages; comfort of local administration, salvage therapy when oral steroids fail or are contraindicated or poorly tolerated and in unilateral disease.²⁴ Otologists prefer IT injection of steroids as delivery of high concentrations of medication to the inner ear is possible while averting the hazards of systemic steroids such as insulin resistance, hypertension, avascular necrosis of hip joint in elderly.¹⁵ Parnes et al documented that of three steroids viz. methylprednisolone, dexamethasone and hydrocortisone, methylprednisolone gives the highest concentration in the inner ear.²⁵ The concentration of steroid in perilymph is high when given via IT route as compared to intravenous. In a study by Bird et al, perilymph concentration of methylprednisolone was found to be 425-1270 fold higher after IT administration compared with intravenous administration.²⁶ Also, plasma levels are 3.5 -5 times lesser following IT versus intravenous administration. Together, these results amount to 2000-4500 fold perilymph concentration with IT administration.²⁶ Based on these results, in our study we used methylprednisolone IT injections, as the available

dexamethasone (4mg/ml) was giving suboptimal results.

The commonly encountered complications with IT steroid infusion are pain in ear, vertigo, middle ear infection, delayed healing or residual tympanic membrane perforation, hearing loss and physical changes in the round window membrane.²⁷ Most of these complications are considerably related to the drug used and the mode of its administration²⁴. Our patients also reported similar complaint of momentary pain, vertigo and hearing loss/heaviness that resolved spontaneously.

In our study, we were unable to decipher any short or long term tinnitus relief or benefit with use of IT methylprednisolone in cochlear tinnitus. Majority of our study participants had cochlear tinnitus persisting in excess of a year before intervention. Animal experiments have shown that cochlear recovery is often irreversible after 3 months of damage. In humans, though some beneficial therapeutic efficacy has been demonstrated in chronic tinnitus, it might not be replicable in all cases and with all steroid classes and formulations. Often, the cochlear lesion may be present asymptotically for long enough before it gets perceived by the patient. In addition, majority of our patients were elderly with a diagnosis of presbycusis, with longstanding disease and irrecoverable damage.

5. Conclusion

Subjective tinnitus in adults has considerable heterogeneity in terms of etiology, presentation and response to treatment. Standard assessment and treatment procedures continue to evolve. Though subjective tinnitus is a benign symptom; it affects the quality of life. Intratympanic steroid injection is therapeutically efficacious and has minimal potential for side effects. However, it may not demonstrate significant benefits in elderly with sensorineural hearing loss, bilateral disease and long-established tinnitus.

6. Source of Funding

None.

7. Conflict of Interest

None.

References

- Shiley SG, Folmer RL, Mcmenomey SO, Cummings CW, Flint PW, Harker LA, et al. Tinnitus and hyperacusis. In: *Otolaryngology Head and Neck Surgery*. Elsevier Mosby; 2005. p. 2832–47.
- Allewa M, Loch WE, Paparella MM. Tinnitus. *Prim Care*. 1990;17:289–97.
- Henry JA, Dennins KC, Schechter MA. General review of Tinnitus: prevalence, mechanism, effects and management. *J Speech Lang Hear Res*. 2005;48:1204–35.
- Rothwell JC, Hallett M, Berardelli A, Eisen A, Rossini P, Paulus W. Magnetic stimulation: motor evoked potentials. The International Federation of Clinical Neurophysiology. *Electroencephalogr Clin Neurophysiol Suppl*. 1999;52:97–103.
- Dodson KM, Sismanis A. Intratympanic perfusion for the treatment of tinnitus. *Otolaryngol Clin North Am*. 2004;37(5):991–1000.
- Schuknecht HF. Ablation therapy for the relief of Meniere's disease. *Laryngoscope*. 1956;66(7):859–70.
- Jackson LE, Silverstein H. Chemical perfusion of the inner ear. *Otolaryngol Clin North Am*. 2002;35(3):639–53.
- Stouffer JL, Tyler RS. Characterization of Tinnitus by Tinnitus Patients. *J Speech Hearing Disord*. 1990;55(3):439–53.
- Pitovski DZ, Drescher MJ, Drescher DG. Glucocorticoid receptors in the mammalian inner ear: RU 28362 binding sites. *Hearing Res*. 1994;77(1-2):216–20.
- Shirwany NA, Seidman MD, Tang W. Effect of transtympanic injection of steroids on cochlear blood flow, auditory sensitivity and histology in the guinea pig. *Am J Otol*. 1998;19:230–5.
- Silverstein H, Choo D, Rosenberg SI, Kuhn J, Seidman M, Stein I, et al. Intratympanic Steroid Treatment of Inner Ear Disease and Tinnitus (Preliminary Report). *Ear Nose Throat J*. 1996;75(8):468–71.
- Yilmaz I, Yilmazer C, Erkan AN, Aslan SG, Ozluoglu LN. Intratympanic dexamethasone injection effects on transient-evoked otoacoustic emission. *Am J Otolaryngol*. 2005;26(2):113–7.
- Hamid M. Issues, indications and controversies regarding intratympanic steroid perfusion. *Curr Opin Otolaryngol Head Neck Surg*. 2008;16:434–40.
- Silverstein H, Jackson LE, Rosenberg SI. Silverstein Microwick™ for treatment of inner ear disease. *Oper Tech Otolaryngol Head Neck Surg*. 2001;12(3):144–7.
- Chandrasekhar SS, Rubinstein RY, Kwartler JA, Gatz M, Connelly PE, Huang E, et al. Dexamethasone pharmacokinetics in the inner ear: Comparison of route of administration and use of facilitating agents. *Otolaryngol Head Neck Surg*. 2000;122(4):521–8.
- Silverstein H, Rowan PT, Olds MJ, Rosenberg SI. Inner ear perfusion and the role of round window patency. *Am J Otol*. 1997;18:586–9.
- Chelikh L, Teixeira M, Martin C, Sterkers O, Ferrary E, Couloigner V, et al. High Variability of Perilymphatic Entry of Neutral Molecules Through the Round Window. *Acta Oto-Laryngologica*. 2003;123(2):199–202.
- Plontke SK, Salt AN. Simulation of Application Strategies for Local Drug Delivery to the Inner Ear. *J Otorhinolaryngol Relat Spec*. 2006;68(6):386–92.
- Plontke SKR, Wood AW, Salt AN. Analysis of Gentamicin Kinetics in Fluids of the Inner Ear with Round Window Administration. *Otol Neurotol*. 2002;23(6):967–74.
- Chandrasekhar SS. Intratympanic Dexamethasone for Sudden Sensorineural Hearing Loss: Clinical and Laboratory Evaluation. *Otol Neurotol*. 2001;22(1):18–23.
- Sakata E, Itoh A, Itoh Y. Treatment of cochlear tinnitus with dexamethasone infusion into the tympanic cavity. *Int Tinnitus J*. 1996;2:129–35.
- Cesarani A, Capobianco S, Soi D, Giuliano DA, Alpini D. Intratympanic dexamethasone treatment for control of subjective idiopathic tinnitus: our clinical experience. *Int Tinnitus J*. 2002;8:111–4.
- Hoffer ME, Wester D, Kopke RD, Weisskopf P, Gottshall K. Transtympanic management of tinnitus. *Otolaryngol Clin North Am*. 2003;36(2):353–8.
- Doyle KJ, Bauch C, Battista R, Beatty C, Hughes GB, Mason J, et al. Intratympanic Steroid Treatment: A Review. *Otol Neurotol*. 2004;25(6):1034–9.
- Parnes LS, Sun AH, Freeman DJ. Corticosteroid Pharmacokinetics in the Inner Ear Fluids: An Animal Study Followed by Clinical Application. *Laryngoscope*. 1999;109(S91):1–17.
- Bird PA, Begg EJ, Zhang M, Keast AT, Murray DP, Balkany TJ, et al. Intratympanic Versus Intravenous Delivery of Methylprednisolone to Cochlear Perilymph. *Otol Neurotol*. 2007;28(8):1124–30.
- Edmunds AL. Potential Complications Associated with Steroid Use in the Middle and Inner Ear. *Ear Nose Throat J*. 2007;86(11_suppl):24–7.

Author biography

Manish Gupta Professor and HOD

Monica Gupta Professor

Satish Kumar Lecturer

Cite this article: Gupta M, Gupta M, Kumar S. **Comparative Efficacy of intra-tympanic methylprednisolone injections in different concentrations on subjective cochlear tinnitus.** *IP J Otorhinolaryngol Allied Sci* 2020;3(3):91-96.