

Content available at: <https://www.ipinnovative.com/open-access-journals>

IP Journal of Otorhinolaryngology and Allied Science

Journal homepage: <https://www.joas.co.in/>

Case Report

Dysphagia following parkinson's - A case study

Kritika Arora¹, Dipti Gupta^{1,*}, Puranjit Kar¹, Abhay Nagpal¹, Gurbax Singh¹

¹Dept. of Audiology, Guru Gobind Singh Medical College and Hospital, Faridkot, Punjab, India



ARTICLE INFO

Article history:

Received 27-05-2023

Accepted 15-07-2023

Available online 11-08-2023

Keywords:

Dysphagia

Parkinson's disease

MASA

Masako maneuver

Mendelsohn maneuver

ABSTRACT

Dysphagia has a number of common causes, including Parkinson's disease. The prevalence ranges from 11% to 87% depending on the disease stage, the length of the condition, and the method of assessment. Parkinson's disease can affect any or all of the swallowing stages. In this case study, a 72-year-old patient with Parkinson's disease is shown to have acquired dysphagia, aspiration, and feeding issues. In this article, the patient is followed as his swallowing status changes after having Parkinson's disease. Various therapy strategies are performed, with a focus on the usage of swallowing maneuvers. This case study emphasizes the significance of a thorough assessment and customized intervention plan for controlling dysphagia. The management involved the dysphagia team's multidisciplinary members, but the speech-language pathologist had a key role in these choices.

This is an Open Access (OA) journal, and articles are distributed under the terms of the [Creative Commons Attribution-NonCommercial-ShareAlike 4.0 License](#), which allows others to remix, tweak, and build upon the work non-commercially, as long as appropriate credit is given and the new creations are licensed under the identical terms.

For reprints contact: reprint@ipinnovative.com

1. Introduction

Dysphagia is a medical condition that affects the ability to swallow properly. Acc. to Jeri A (1998)]¹ "Dysphagia is a medical condition characterized by difficulty or discomfort in swallowing". The common symptoms of dysphagia include coughing or choking while eating, feeling like food stuck in the throat or chest, regurgitation of food or liquids, pain while swallowing, recurring pneumonia or respiratory infections. Dysphagia is of different types (oral preparatory, oral dysphagia, pharyngeal dysphagia, esophageal dysphagia) depending on the signs and symptoms. The SLP has a major role in diagnosing and treating only the oral preparatory, oral and pharyngeal dysphagia.

Dysphagia can affect people of all ages from infants to the elderly however elderly suffer more from this condition. Due to lack of epidemiological studies on dysphagia, the incidence and prevalence of dysphagia is limited. Acc.

to National foundation of swallowing disorders, Patel et al (2018) the incidence and prevalence of dysphagia is estimated acc.to different (i) settings – acute and chronic geriatric care (68%) followed by general hospitals (30%) and (ii) diseases - Parkinson's disease (90%), head and neck cancer (48%), stroke (27%), dementia (15%) and endotracheal intubation (5-10%).² It can be brought on by a wide range of conditions, including neurological disorders, gastrointestinal disorders, progressive diseases (such as Parkinson's disease and amyotrophic lateral sclerosis), iatrogenic causes (such as tracheostomy, radiation therapy, and chemotherapy), as well as other or related conditions like structural abnormalities, respiratory disorders, head and neck cancer, aging, etc. It is a severe disorder that can cause aspiration pneumonia, dehydration, and dehydration.¹ Diagnosis includes a thorough evaluation of anatomical structures, imaging tests and swallowing studies. Treatment options may include lifestyle modifications, medications or surgery, swallowing therapy to improve swallowing functions.

* Corresponding author.

E-mail address: diptidg15@gmail.com (D. Gupta).

2. Case Presentation

A 72-year-old man who had been having trouble swallowing and aspirating for the past few months was admitted to the hospital's tertiary care unit. He claimed that he felt like food was becoming caught in his throat and that he needed to swallow several times to clear it. Due to his trouble swallowing, he lost a lot of weight over a short period of time.

2.1. Medical history

The patient had a history of hypertension, diabetes (type II) and Parkinson's disease. Patient took amlodipine and syndopa for hypertension and dopamine deficiency respectively. Patient also had no history of stroke, gastrointestinal disorders, respiratory conditions or head and neck surgeries.

2.2. Clinical examination

On physical examination, patient appeared to have a drooping posture along with weakness in upper and lower limbs. His vital signs were within normal limits. Examination of the head and neck showed no abnormalities. Cranial nerve examination Revealed signs shown in Table 1. On speech and language evaluation the following results were obtained–

Oral Peripheral Motor Examination Revealed the Following Results.

1. *Lips* – The patient demonstrated weak lip closure and strength during pucker and whistle tasks.
2. *Dentition* – The patient had missing teeth and uses dentures
3. *Tongue* – The patient had difficulty protruding the tongue beyond the lips and demonstrated reduced strength during protrusion, elevation, retraction and lateralization.
4. *Palate* – The patient exhibited inadequate elevation and reduced mobility of the soft palate during the phonation of 'ahh' and also had reduced strength during the nasal consonant 'n' production.
5. *Jaw* – The patient had adequate jaw opening and closing range of motion but demonstrated reduced strength during jaw lateralization and protrusion tasks.
6. *Larynx* – The patient had delayed laryngeal elevation during swallowing along with weak cough reflex.

The vegetative skills of the patient such as blowing, sucking, chewing, biting and coughing were also affected.

Overall, the oral peripheral motor examination results revealed reduced strength and coordination of the muscles involved in swallowing, contributing to dysphagia.

2.3. Cranial nerve examination

Following nerves were discovered to be impacted during investigation of the cranial nerves involved in swallowing, which led to weakening in the muscles they innervate and ultimately affected movements of the parts these muscles innervate (Table 1).

Table 1: Cranial nerve examination

Cranial Nerve	Responses
Trigeminal	Inadequate jaw pressure Jaw movements affected (lateralization and against resistance) Impaired chewing Weakness of temporalis and masseter muscle
Facial	Poor lip seal Alternate motion of lips (ee, oo) affected Smile, pucker unable to perform Puffing of cheeks affected Facial muscle weakness
Glossopharyngeal	Reduced soft palate elevation Reduced gag reflex Pharyngeal constrictor weakness
Vagus	Abnormal movement of vocal folds during phonation
Hypoglossal	Restricted range of motion of the tongue movements (lateralization, protrusion, elevation retraction, against resistance) all affected

2.4. Speech assessment

The FDA (Frenchay Dysarthria Assessment) and Apraxia Battery for Adults (ABA-2) were administered to rule out the possibility of speech deficits and apraxia component in the patient. No abnormality was detected in Apraxia Battery for Adults (ABA-2).

2.5. Franchay's dysarthria assessment

Administration of FDA revealed the presence of hypokinetic dysarthria (Parkinson's disease) which was further confirmed by looking for the confirmatory signs which are shown in Table 2.

2.6. Four finger test revealed

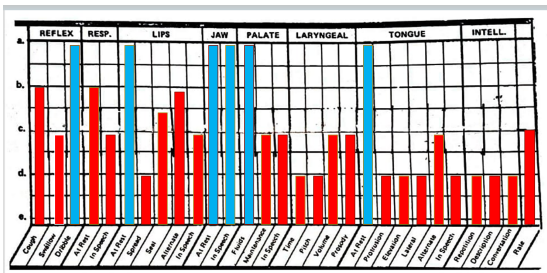
The finger developed by Jeria A. Logemann,¹ placing the finger on the submandibular region, finger on thyroid bone, on thyroid cartilage.

The patient is Introduced to swallow.

The four finger test developed by Jeri A. Logemann² includes placing the first finger on the submandibular region, second finger on hyoid bone, third & fourth fingers

Table 2: Confirmatory neurological signs in the patient.

Bradykinesia	Present
Akinesia	Present
Rigidity	Present
Gait	Festinating Gait (Shuffling, Small Baby Steps)
Posture	Stooped Posture (Forward Bent)
Facial Expression	Masked Face
Extremities	Flexed Elbows, Arms and Knees

**Fig. 1:** FDA scoring sheet

on the thyroid cartilage.

2.7. The mann assessment of swallowing ability (MASA)

It is an instrument designed for bedside evaluation for patients with swallowing issues. It measures 24 different areas to gauge a patient's swallowing abilities. On administration of MASA on the patient the total score obtained was 140 out of 200 which reveals moderate dysphagia. The Masa score for individual domain is shown in Table 3.

3. Instrumental Evaluation

3.1. Endoscopic evaluation

Endoscopic evaluation reveals that epiglottis, bilateral valleculae, aryepiglottic folds, pyriform sinuses were normal with bilaterally swollen vocal cords.

4. Electrolottography

Vocal fold irregularity and a compromised contact quotient are both revealed by electroglottography.

4.1. Provisional diagnosis

The detailed subjective and objective assessment revealed moderate dysphagia of pharyngeal type. The provisional diagnosis made was hypokinetic dysarthria with dysphagia

Table 3: MASA scoring

Domain	Scoring	Explanation
Alertness	8	Drowsy – Fluctuating Awareness / Alert Level
Cooperation	10	Cooperative
Auditory Comprehension	10	No Abnormality Detected
Respiration	10	No Evidence of Abnormality
Respiratory Rate for Swallow	3	Patient can achieve nasal breathing for short period
Dysphasia	5	No Abnormality Detected
Dyspraxia	5	No Abnormality Detected
Dysarthria	2	Speech Unintelligible
Saliva	5	No Abnormality Detected
Lip Seal	2	Incomplete Closure or Limited
Tongue Movement	4	Minimal movement
Tongue Strength	2	Gross Weakness
Tongue Coordination	5	Gross Incoordination
Oral Prepration	6	Minimal Chew
Gag	4	Diminished Bilaterally
Palate	4	Minimal Movement (Nasal Air Escape)
Bolus Clearance	8	Significant Clearance, Minimal Residue
Oral Transit	8	Delay Greater Than 1 Sec
Cough Reflex	5	Strong Reflexive Cough
Voluntary Cough	5	Attempt Inadequate
Voice	6	Hoarse, difficulty with pitch and volume control
Trache	10	No Trache Required
Pharyngeal Phase	8	Laryngeal Elevation Restricted
Pharyngeal Phase	5	Coughing Triggered After Swallow

5. Treatment

The main objective of treatment was to restore oral feeding while continuously ensuring appropriate nutrition and hydration as well as safe swallowing. The management strategies included therapeutic and compensatory treatment strategies. The compensatory treatment methods are those that regulate food flow and get rid of symptoms like aspiration in the patient while not necessarily altering the swallowing physiology.

1. Postural adjustments – This involves looking for the best head and neck position that results in no symptoms

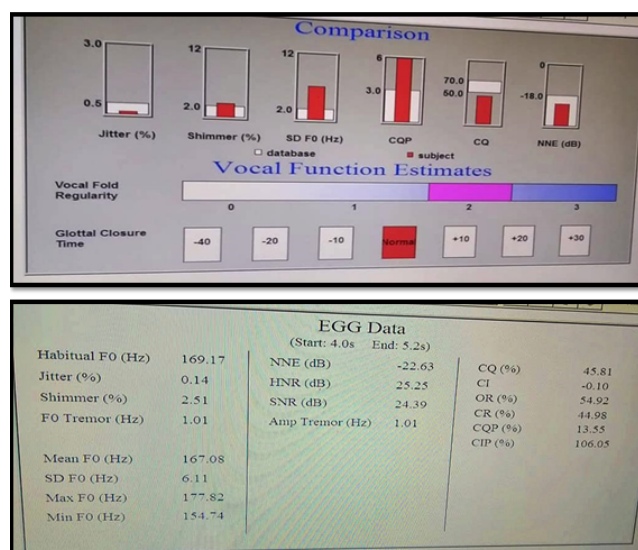


Fig. 2: EGG data

of aspiration while tilting patient head to different positions during swallowing. In this case chin tuck position was found out to be the best position that led to no symptoms of aspiration and the patient was instructed to swallow in the same way and position.

2. Modifying volume and speed of food presentation – patient had a weakened pharyngeal swallow and required two or more swallows per bolus to clear the remaining residue. The patient had a habit of engulfing the food bolus too quickly resulting in collection of food residue in the pharynx thus causing aspiration. Thus, the patient was instructed to simply take small quantity of a food item, chew the bolus properly at a slower rate, thereby eliminating any risk of aspiration.

5.1. The therapy procedures included

1. Oral control and oral & pharyngeal range of motion exercise – various oral motor control exercises were demonstrated which included, range of motion and resistance exercises of the tongue, lip and jaw; range of motion of pharyngeal exercises (vocal fold adduction exercises)
2. Swallowing maneuvers – Mendelsohn and masako maneuvers were administered on the patient. The goal of Mendelsohn maneuver is to increase the extension and duration of the laryngeal elevation thereby increasing the duration and width of the cricopharyngeal opening. The patient was instructed to first perform the maneuver with saliva and then with the bolus. Similarly, the goal of masako maneuver is to achieve complete movement of pharyngeal constrictors and strengthen the base of the tongue to improve swallowing in Parkinson's disease patient. These were

the two maneuvers that the patient was instructed to perform in both therapy and at home as a part of home training.

6. Results

Tables 4 and 5 shows the post therapy outcomes of the patient after applying customized intervention plan.

Table 4:

Pre-Therapy	Post Therapy	Percentage Achieved
Prior Patient was not able to Elevate, protrude, lateralize, retract tongue	Now the patient is able to Elevate, protrude, lateralize, retract tongue	Accuracy attained – 60-70%
Hold a position of articulators	Can hold the articulators in different position	Accuracy attained – 70%
Reduced range of motion of the articulators	Adequate range of motion of articulators	Accuracy attained – 70-75%
Affected movement against resistance	Able to resist the articulators against external force applied to some extent	Accuracy attained – 50-60%
Palatal movements		
Significant Hyper nasality	Enhanced palatal movements	Accuracy attained – 60%
	No significant change	Accuracy attained – 10-20%

Table 5:

Pre – Therapy	Post- Therapy
Masa Score – 140	Masa Score – 169
Severity – Moderate	Severity – mild
Aspiration & Choking While Swallowing	No Aspiration & Choking While Swallowing
Cough During Or After Meal	Significantly Reduced

7. Discussion

Parkinson's disease is becoming more frequent as the global human population is aging [Tysnes (2017, August)].³ In Parkinson's disease, dysphagia is very common with serious and negative consequences for physical health and quality of life [Smith].⁴ Today, the most common treatment for dysphagia focuses on changing the texture of the diet, although there are other techniques aimed at improving the

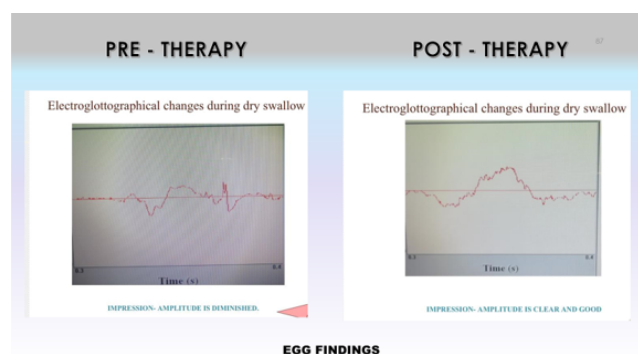


Fig. 3: This is electroglottography (EGG)

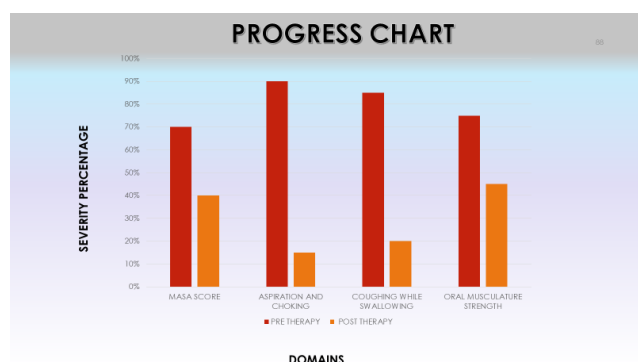


Fig. 4: Domains

quality of life of the patients suffering from dysphagia. [Troche].⁵

This case study highlights different therapeutic techniques which were used during management. It greatly emphasized on compensatory procedures as well as swallowing maneuvers to treat the signs and symptoms of the patient. Use of MASAKO and Mendelsohn maneuver eliminated aspiration and swallowing difficulty. Hence this study rationalizes the importance of swallowing maneuvers along with lifestyle modifications in treating patients with dysphagia.

Like this study, preceding studies verified that use of appropriate swallowing maneuvers and compensatory strategies in dysphagia management lead to enhancement of swallowing functions such as reduction of aspiration in patients with Parkinson's disease.

Felix et.al. emphasized the implementation of swallowing maneuvers such as the Mendelsohn and Masako and postural adjustments to be used as therapeutic techniques for oropharyngeal dysphagia in patients with Parkinson's disease.⁶

Argolo et.al. investigated the effect of motor swallowing exercises, on swallowing dynamic, quality of life and swallowing complaints in Parkinson's disease and found that these exercises may reduce the swallowing disorders in Parkinson's disease patients and impact positively on the

quality of life and swallowing complaints in individuals with Parkinson's disease.⁷

In his case study, which was designed to examine the impact of concurrently applying postural techniques and EMST on the enhancement of swallowing, author Byeon reported that the use of postural methods and expiratory muscular strengthening training (EMST) as a part of intervention for dysphagia in patients with Parkinson's disease resulted in significant improvements in swallowing.⁸

The effects of using the tactics, such as compensatory strategies and swallowing maneuvers, mentioned in the chosen papers support an improvement in the ability to swallow functions in Parkinson's disease patients.⁹ Similar outcomes were attained in this case study, where the patient received the same therapy approaches and had a noticeable increase in their ability to swallow. This case study thus emphasizes the significance of adopting compensatory techniques and swallowing maneuvers as a part of the treatment in managing individuals who have dysphagia caused due to Parkinson's disease.

8. Source of Funding

None.


9. Conflict of Interest


None.

References

- Logemann JA. The Evaluation and Treatment of Swallowing Disorders. *Curr Opin Otolaryngol Head Neck Surg.* 1998;6(2):345–400.
- Patel DA, Krishnaswami S, Steger E, Conver E, Vaezi MF, Ciucci MR, et al. Economic and survival burden of dysphagia among inpatients in the United States. *Dis Esophagus.* 2018;31(1):1–7.
- Tysnes OB, Storstein A. Epidemiology of Parkinson's disease. *J Neural Transmission.* 1996;124(8):901–5.
- Smith SK, Roddam H, Sheldrick H. Rehabilitation or compensation: time for a fresh perspective on speech and language therapy for dysphagia and Parkinson's disease? *Int J language Commun Dis.* 2012;47(4):351–64.
- Troche MS, Sapienza CM, Rosenbek JC. Effects of bolus consistency on timing and safety of swallow in patients with Parkinson's disease. *Dysphagia.* 2008;23(1):26–32.
- Felix VN, Corrêa SM, Soares RJ. A therapeutic maneuver for oropharyngeal dysphagia in patients with Parkinson's disease. *Clinics.* 2008;63(5):661–6.
- Argolo N, Sampaio M, Pinho P, Melo A, Nóbrega AC. Do swallowing exercises improve swallowing dynamic and quality of life in Parkinson's disease? *Neuro Rehabil.* 2013;32(4):949–55.
- Byeon H. Effect of simultaneous application of postural techniques and expiratory muscle strength training on the enhancement of the swallowing function of patients with dysphagia caused by parkinson's disease. *J Physical Ther Sci.* 2016;28(6):1840–3.
- Liria RL, Egeda JP, Vega-Ramírez FA, Aguilar-Parra JM, Ramos RT, Morales-Gázquez MJ, et al. Treatment of Dysphagia in Parkinson's Disease: A Systematic Review. *Int J Environ Res Public Health.* 2020;17(11):4104.

Author biography

Kritika Arora, Intern GGSMCH, Faridkot  <https://orcid.org/0000-0002-6538-2332>

Dipti Gupta, Assistant professor (Audiology & SLP)
 <https://orcid.org/0000-0002-7551-2495>

Puranjit Kar, Lecturer

Abhay Nagpal, Intern GGSMCH, Faridkot  <https://orcid.org/0000-0003-4355-409X>

Gurbax Singh, Professor and Head

Cite this article: Arora K, Gupta D, Kar P, Nagpal A, Singh G.
Dysphagia following parkinson's - A case study. *IP J Otorhinolaryngol Allied Sci* 2023;6(2):46-51.