

Content available at: <https://www.ipinnovative.com/open-access-journals>

IP Journal of Otorhinolaryngology and Allied Science

Journal homepage: <https://www.joas.co.in/>

Case Report

A rare presentation of recurrent tongue tie

Deepalakshmi Tanthry¹, Gururaj Tanthry², Rohan Shetty^{1,*}

¹Dept. of ENT, A.J. Institute of Medical Sciences and Research Centre, Mangaluru, Karnataka, India

²Dept. of Anaesthesia, A.J. Institute of Medical Sciences and Research Centre, Mangaluru, Karnataka, India



ARTICLE INFO

Article history:

Received 20-04-2023

Accepted 22-05-2023

Available online 23-05-2023

Keywords:

Swelling

Ankyloglossia

Mucocoele

ABSTRACT

Ankyloglossia or tongue-tie is the result of a short, tight, lingual frenulum causing difficulty in speech articulation due to limitation in tongue movement. Ankyloglossia is a common finding in infants. Prevalence ranges between 4.2% and 10.7%. Although lingual frenectomy is a common technique it is a sensitive surgical procedure, the anatomic and topographic lingual frenulum makes the site vulnerable to various intraoperative and postoperative complications. In this case study, we have reported a 2-year-old male child with prior history of a frenectomy, presented with difficulty in speech and restricted tongue movements. On examination, a 1x1cm, solitary swelling was noted in the region of the lingual frenulum, firm, cystic, and non-tender. Tongue movements were restricted with an inability to perform protrusion beyond the vermillion border of the lips. Under general anesthesia, the child underwent revision frenectomy, excision of the swelling, and release of fibrous tissue adjacent to the swelling. Intraoperatively protrusion of the tongue was examined and found to have improved. The specimen was sent for histopathology which was reported as organizing mucocoele. The Child was reviewed after 6 months, tongue movements were seen to have improved substantially in all ranges of motion.

This is an Open Access (OA) journal, and articles are distributed under the terms of the [Creative Commons Attribution-NonCommercial-ShareAlike 4.0 License](#), which allows others to remix, tweak, and build upon the work non-commercially, as long as appropriate credit is given and the new creations are licensed under the identical terms.

For reprints contact: reprint@ipinnovative.com

1. Presentation

A 2-year-old male child presented with complaints of difficulty in speech and protrusion of the tongue since birth. Parents give the history of the child undergoing frenectomy 6 months back after which tongue movement was further restricted. On examination, a cystic swelling was noted below the tongue measuring 1 *1cms firm, non tender, and fixed to the floor of the mouth. Restricted tongue movements were noted in all ranges of motion. Other oral cavity structures are normal. Speech affected.

1.1. Procedure

The child underwent revision frenectomy under general anesthesia. Infiltration was given submucosally and dissection done from the margins and around the cystic swelling followed by the release of fibrous tissue adjacent to the swelling. Tongue protrusion was assessed intraoperatively, and could be protruded out beyond the vermillion border of the lower lip. The postoperative period was uneventful. On the 3rd post-operative day, the child was able to protrude his tongue out and improvement was noted in all ranges of motion. The child was advised to follow up with speech therapy

* Corresponding author.

E-mail address: mcshetty1095@gmail.com (R. Shetty).

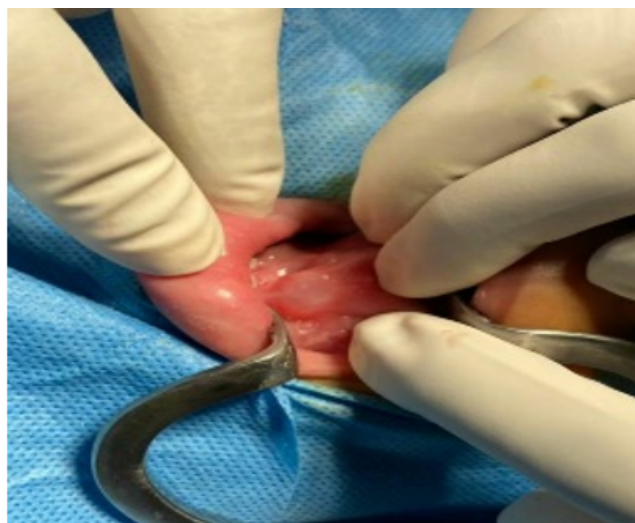

Fig. 1: Cystic swelling on the floor of the mouth

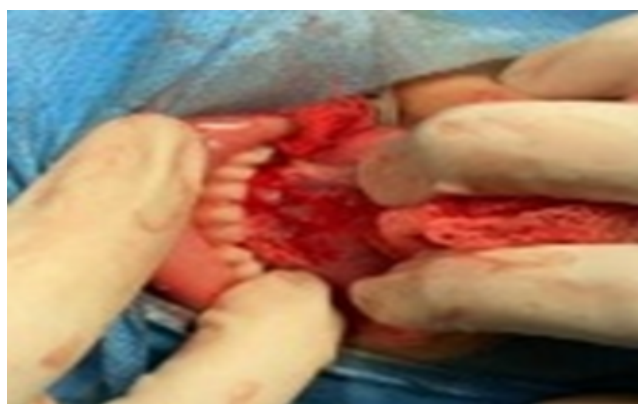

Fig. 2: Post excision of swelling, fibrous tissue adhesion, and frenectomy

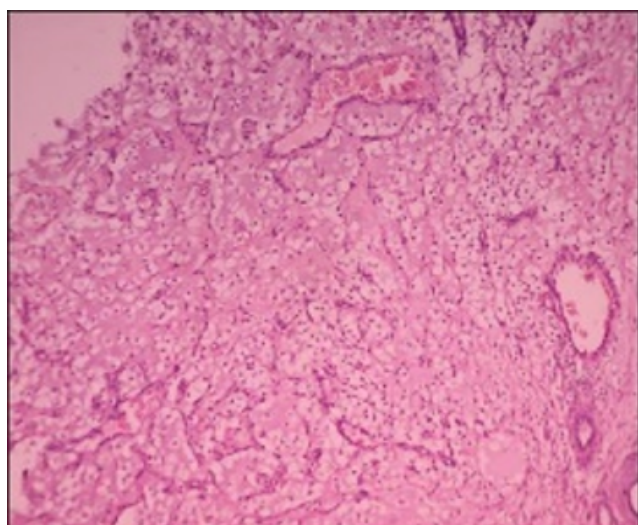


Fig. 3: Organising mucocoele




Fig. 4: Child was able to protrude his tongue easily on 1 month follow up

2. Discussion

Etymologically, "ankyloglossia" originates from the Greek words "agkilos" (curved) and "glossa" (tongue). Ankyloglossia or tongue-tie is the result of a short, tight, lingual frenulum causing difficulty in speech articulation due to limitation in tongue movement. The lingual frenulum may be fibrous or muscular, and the tie may be complete partial, or complete.

In many individuals, ankyloglossia is asymptomatic; the condition may resolve spontaneously or affected individuals may learn to compensate adequately for their decreased lingual mobility. Some individuals, however, benefit from surgical intervention frenotomy, frenectomy or frenuloplasty for their tongue-tie.¹ The prevalence of ankyloglossia reported in the literature varies from 0.1% to 10.7%. Ankyloglossia in children can lead to a range of problems, such as difficulties breastfeeding, speech impediments, poor oral hygiene, and being embarrassed by peers during childhood and adolescence.² Frenotomy (the clipping of the lingual frenulum) is the most indicated technique for babies with ankyloglossia since it is a conservative, simple and quick procedure that may be performed in outpatient department settings during the initial consultation.³ The limitation of this technique is the possibility of recurrence and the need to perform complementary procedures to release the tongue satisfactorily. Frenectomy corresponds to the complete excision of the frenulum.³ This procedure is more invasive and difficult to be performed in young children, although the results are more predictable, decreasing the recurrence rate.⁴ Surgery should be performed before the child develops abnormal swallowing and speech patterns.

When the procedure is performed in older children, they should be referred to a speech therapist to reestablish the normal functions of the tongue.³ Laser technology is an alternative to conventional techniques, presenting several advantages such as shorter operative working time, tissue cauterization and sterilization, hemostasis, less local anesthesia requirement, and fewer postoperative complications (pain, swelling and infection).³ A laser also enhances access and visualization due to the lack of interposed instruments and bleeding in the operative field. The complications following lingual frenectomy are excessive bleeding or hemorrhage due to injury to the submental and sublingual artery and deep lingual veins, formation of retention cyst, mucocoele or ranula, its etiology is a partial blockage of Wharton's duct while suturing or injury while delivering local anesthesia, Sublingual hematoma formation, development of sublingual and submandibular space infection, reattachment or recurrence of frenal attachment caused by the development of a fibrous scar at the site of the excision or inadequate releasing incisions and incomplete removal of frenal attachment at the time of lingual frenectomy, development of new speech disorder or worsening of existing speech disorder caused by scar tissue formation and numbness and paresthesia of the tongue and neighboring soft tissues.⁵ Although lingual frenectomy is a common and technique-sensitive surgical procedure, the anatomic and topographic lingual frenum makes the site vulnerable to various intraoperative and postoperative complications. Therefore, comprehensive knowledge and understanding of the various etiology of complications associated with lingual frenectomy are essential to provide optimal postoperative care and achieving good clinical outcomes and overall patient satisfaction

3. Conclusion

To conclude it should be noted that although a lingual frenectomy is a fairly simple technique it must be done with utmost care as it could result in rare complications like

an organizing mucocoele which the patient came with in our case. A revision frenectomy with mucocoele excision under GA followed up with the required speech therapy was found to be effective in treating the condition as well rehabilitation. It can therefore be considered as a reliable and safe technique.

4. Source of Funding

None.

5. Conflict of Interest

None.

References

1. Chaubal V, Dixit M. Ankyloglossia and its management. *J Indian Soc Periodontol*. 2011;15(3):270–2.
2. Sehgal LM, Stephenson R, Dawes M, Feldman P. Prevalence, diagnosis, and treatment of ankyloglossia. *Canadian Fam Physician*. 2007;53(6):1027–33.
3. Janqueira MA, Cunha N, Sakai VT. Surgical techniques for the treatment of ankyloglossia in children: a case series. *J Appl Oral Sci*. 2014;22(3):241–8.
4. Manfro AR, Manfro R, Bortoluzzi MC. Surgical treatment of ankyloglossia in babies—case report. *Int J Oral Maxillofac Surg*. 2010;39(11):1130–2.
5. Lingual frenectomy, postoperative complications: A critical review Giulia Palandrani. Available from: <https://www.dentistry33.com/clinical-cases/oral-surgery/454/lingual-frenectomy-post-operative-complications-a-critical-review.html>.

Author biography

Deepalakshmi Tanthry, Associate Professor

Gururaj Tanthry, Professor

Rohan Shetty, PG Student

Cite this article: Tanthry D, Tanthry G, Shetty R. A rare presentation of recurrent tongue tie. *IP J Otorhinolaryngol Allied Sci* 2023;6(1):27-29.