



## Case Report

# Unusual presentation of laryngotracheal injury due to electric burn

Vikasdeep Gupta<sup>1,\*</sup>, Neha Salaria<sup>2</sup>, Naveen Sharma<sup>2</sup>, Vandana<sup>3</sup>, Gagandeep Kaur<sup>1</sup>

<sup>1</sup>Dept. of Otolaryngology Head neck Surgery, All India Institute of Medical Sciences, Bathinda, Punjab, India

<sup>2</sup>Dept. of Otolaryngology Head neck Surgery, BPS Government Medical College, Khanpur Kalan, Sonapat, Haryana, India

<sup>3</sup>Dept. of R.I. Ophthalmology, PGIMS, Rohtak, Haryana, India



## ARTICLE INFO

### Article history:

Received 10-06-2020

Accepted 28-07-2020

Available online 24-10-2020

### Keywords:

Laryngotracheal

Trauma

## ABSTRACT

Laryngeal trauma is exceptionally rare due to the protective effect of the mandible and sternum and the laryngotracheal framework's elastic nature. Trauma to the larynx can be life-threatening and cause not only mortality but longterm upper aerodigestive morbidity.

Here is a case of a 37 year-old male with electric burn of laryngotracheal region.

© 2020 Published by Innovative Publication. This is an open access article under the CC BY-NC license (<https://creativecommons.org/licenses/by-nc/4.0/>)

## 1. Introduction

Laryngeal trauma is exceptionally rare due to the protective effect of the mandible and sternum and the laryngotracheal framework's elastic nature. Trauma to the larynx can be life-threatening and cause not only mortality but longterm upper aerodigestive morbidity.<sup>1</sup>

Trauma to the larynx may be caused by a blunt or a penetrating injury, the former being more common. Due to the majority of cases being caused by blunt trauma, closed injuries are usual. Penetrating neck injuries are those neck injuries that extend deep to or across the platysma. Open or penetrating injuries of the larynx are exceptional and mainly as a result of homicidal stab or cut throat grievances in addition to gunshot injuries. These account for most of the mortalities commonly due to excessive vascularity of this region consequential to major blood vessels in this zone.<sup>2</sup>

Prompt and proper diagnosis and management of acute laryngeal trauma is necessary as the clinical picture varies considerably on the basis of not only the mechanism of injury but also on the severity and location. The following manifestation of laryngeal trauma is a unique report where not only the mechanism but also the form of laryngotracheal

injury sustained and patient presentation is distinct.

## 2. Case Report

A 37 years old male patient presented to the emergency department with history of electric burn 2 hours back when his neck came in contact with an open wire during travelling on the roof of a bus.

The patient was unable to talk.

On general physical examination patient was conscious, cooperative, and well oriented to time place and person.

On examination, there was a cutthroat wound on the neck around 8 cm horizontally running 2cm above the suprasternal notch. The skin on the wound edges had superficial burns. Both sides' sternomastoid muscles were exposed laterally and were intact. Thyroid cartilage of larynx was cut from the middle transversely left side piriform sinus mucosa was cut, and salivary secretion with air was leaking through it on asking the patient to swallow. In the lower part, trachea was cut transversely at the *third–fourth* tracheal ring level and was exposed. The patient was breathing comfortably from this natural tracheotomy. SpO<sub>2</sub> at the time of presentation was 95 % on room air. No evidence of respiratory distress was there. Blood pressure of the patient was 116/64mm of mercury in supine position

\* Corresponding author.

E-mail address: [vdgupta88@gmail.com](mailto:vdgupta88@gmail.com) (V. Gupta).

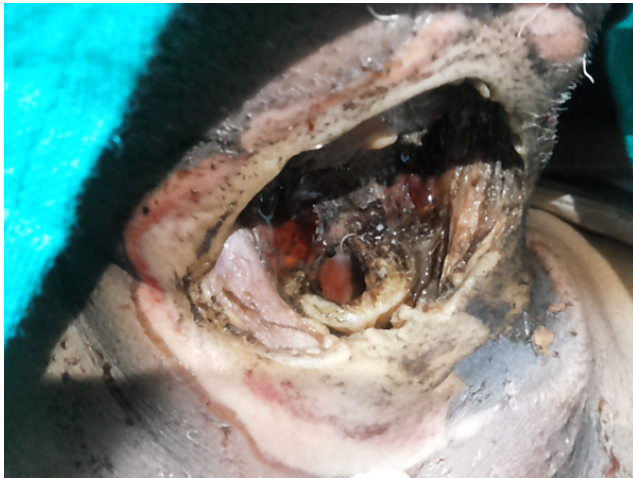
and pulse was 86/min.

All the tissues from the cut thyroid cartilage to the exposed tracheal ring were charred, including the thyroid gland, cricoid cartilage, upper tracheal rings, hypopharynx. No active bleeding was present as all vessels were charred/cauterized by the electric current.

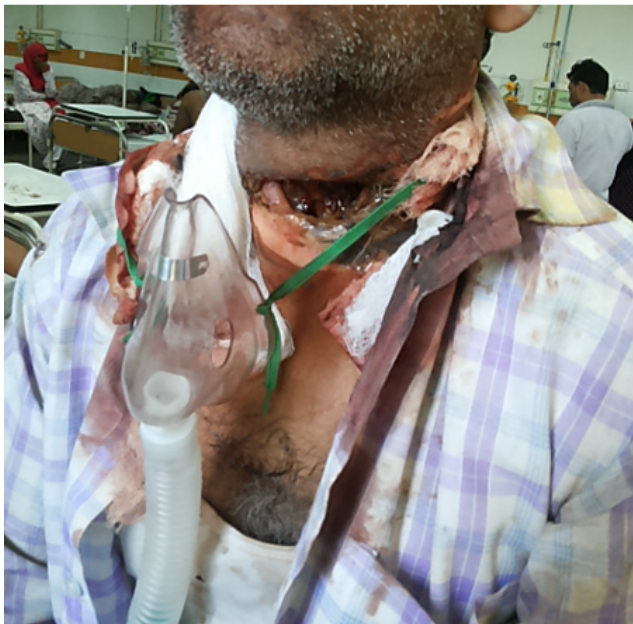Neurological examination was found to be normal ruling out cervical spine injury.

No other injury was present in the patient.

Cuffed Tracheostomy tube no. 7.5 was inserted through the natural tracheostoma. Primary repair of the remaining piriform mucosa was done. The wound was closed in layers with vicryl 3-0. A negative suction drain was kept.



**Fig. 1:**



**Fig. 2:**

### 3. Discussion

Injury to the upper aerodigestive tract is not usually majorly due to its elastic framework, as well as its location where it is protected superiorly by the maxilla and mandible, which is inferiorly by the sternum and posteriorly by the cervical vertebrae. But once laryngotracheal trauma is sustained, there are significant chances of morbidity and mortality. In fact, prehospital mortality has been reported to vary from 15% to 81% if intrathoracic injuries are included.<sup>3</sup>

Laryngotracheal trauma can occur by varying mechanisms. Based on the mechanism of injury it can either be a blunt or penetrating trauma. Motor vehicle accidents are more frequently associated with blunt trauma.<sup>4</sup> Other than roadside accidents, sports events like skiing, water sports, motorcycle and bicycle races also have an increased likelihood of blunt injuries. Penetrating neck traumas are comparatively less common. Gunshot injuries, stab injuries and cut throat attempts, industrial machinery associated events are more linked to penetrating injuries.<sup>4</sup> The mechanism of penetrating neck injury in the current case was quite exceptional and was a result of a vehicular accident where the patient was sitting on the roof of a bus and was exposed to an actively charged electrical wire.

Penetrating neck injuries are injuries of the neck traversing across the platysma. Although the neck comprises of only 2% of total body surface area, penetrating neck injuries lead to significant mortality and morbidity due to vital structures in this area, namely the aerodigestive tract and the major blood vessels. Mortality is high as a result of airway compromise or torrential exsanguinating hemorrhage.

Laryngeal fractures may lead to significant problems in airway patency, voice production as well as swallowing, although a large number of patients are asymptomatic due to protection provided by the elastic framework and its strategic location. If symptomatic, they may present with varying severity of several symptoms.

Clinical picture is variable depending on location, severity, and mechanism of injury. Features vary from loss of normal anatomic landmarks, crepitus, emphysema, dyspnea, hoarseness of voice, stridor, dysphagia, odynophagia, hemorrhage, haemoptysis. This report highlights a very distinct and rarely seen presentation and focuses on the importance of prompt diagnosis and proper emergent management.

The sequelae of laryngeal trauma is dependent more on the type and mechanism of injury rather than severity of injury, as suggested by Kruger.<sup>5</sup> Acute laryngeal trauma may be grouped into five categories:

1. Minor endolaryngeal hematoma or laceration without detectable fracture
2. Edema, hematoma, minor mucosal disruption without exposed cartilage, nondisplaced fracture noted on CT

3. Massive edema, mucosal tear, exposed cartilage, cord immobility, displaced fracture
4. Same as group 3 but with more than two fracture lines or massive trauma to laryngeal mucosa, and
5. Complete laryngeal separation<sup>6,7</sup>.

The patient in the report presented had a complete transection of laryngeal cartilages; hence can be categorized as belonging of category 5.

All laryngeal injuries do not need active intervention.

#### 4. Source of Funding

None.

#### 5. Conflict of Interest

None.

#### References

1. Watkinson JC, Gilbert RW. Stell and Maran's Textbook of Head and Neck Surgery and Oncology. Hodder & Stoughton Ltd; 2012. p. 280.
2. Sharma SB, Amata AO. Penetrating neck injuries involving the larynx: A report of three cases. *Trauma Emerg Care*. 2016;1:28–32.
3. Peady C. Initial Airway Management of Blunt Upper Airway Injuries: A Case Report and Literature Review. *Australas Anaesth*. 2005;p. 13–21.
4. Ulkumen B, Celik O, Sahin N. Open Laryngeal Fracture: A case report and review of the literature. *Med Sci Discov*. 2015;2(5):304–7.
5. Kragha KO. Acute Traumatic Injury of the Larynx. *Case Rep Otolaryngol*. 2015;2015:1–3.
6. Fuhrman GM, Stieg IFH, Buerk CA. Blunt laryngeal trauma: classification and management protocol. *J Trauma*. 1990;30(1):87–92.
7. Butler AP, O'Rourke AK, Wood BP, Porubsky ES. Acute External Laryngeal Trauma: Experience with 112 Patients. *Ann Otol, Rhinol Laryngol*. 2005;114(5):361–8.

#### Author biography

**Vikasdeep Gupta** Assistant Professor

**Neha Salaria** Assistant Professor

**Naveen Sharma** Assistant Professor

**Vandana** Senior Resident

**Gagandeep Kaur** Senior Resident

**Cite this article:** Gupta V, Salaria N, Sharma N, Vandana, Kaur G. **Unusual presentation of laryngotracheal injury due to electric burn.** *IP J Otorhinolaryngol Allied Sci* 2020;3(3):114-116.